

Republic of Rwanda



Ministry of Health

P. O. Box 84 Kigali

www.moh.gov.rw

Surgery

Clinical Treatment Guidelines

September 2012

Republic of Rwanda



Ministry of Health

P. O. Box 84 Kigali

www.moh.gov.rw

Surgery

Clinical Treatment Guidelines

September 2012

Table of Contents

Acronyms.....	v
Foreword.....	vii
1. Orthopaedic Surgery.....	1
1.1. Upper Limbs Fractures.....	4
1.1.1. Distal Radius & Ulna fractures.....	4
1.1.2. Forearm Shaft Fractures.....	5
1.1.3. Distal Humerus Fractures.....	7
1.1.4. Humeral Shaft Fracture.....	9
1.1.5. Fractures of Proximal Humerus.....	10
1.1.6. Tuberosity Fractures.....	10
1.1.7. Clavicle Fractures.....	11
1.1.8. Scapula Fractures.....	12
1.2. Pelvic and Lower Limb Fractures.....	13
1.2.1. Pelvic Ring Disruption.....	13
1.2.2. Fractures of the Acetabulum.....	16
1.2.3. Trochanteric Fractures.....	18
1.2.4. Femoral Neck Fractures.....	19
1.2.5. Femoral Shaft Fractures.....	20
1.2.6. Distal Femur Fractures.....	20
1.2.7. Patellar Injuries.....	21
1.2.8. Proximal Tibia Fractures.....	22
1.2.9. Tibia-Fibula Fractures.....	23
1.2.10. Fractures of the Distal end of the Tibia.....	24
1.3. Foot fractures.....	25
1.3.1. Ankle Fractures.....	25
1.3.2. Calcaneus Fractures.....	27
1.3.3. Talus Fractures.....	29
1.3.4. Midfoot Fractures.....	31
1.3.5. Fore-Foot Fractures.....	31
1.3.6. Fractures of the Phalanges of the Toes.....	32
1.3.7. Fracture of the Sesamoids of the Great Toe.....	32
1.4. Fractures in Children.....	33
1.4.1. Epiphyseal Fracture.....	33
1.4.2. Supracondylar Fracture of Humerus.....	33

1.4.3. Radial Neck Fracture.....	35
1.4.4. Forearm Fracture.....	35
1.4.5. Pelvic and Lower Limb Fractures.....	35
1.5. Open Fractures.....	36
1.6. Critical care.....	38
1.6.1. Critical Care Severe Traumatic Brain Injury.....	38
1.6.2. Critical Care of Multiple Injuries.....	41
1.7. Dislocations.....	43
1.7.1. General Consideration.....	43
1.7.2. Acromio-Clavicular Joint Dislocation.....	44
1.7.3. Shoulder Dislocations.....	45
1.7.4. Elbow Dislocation.....	47
1.7.5. Hip Dislocation.....	48
1.7.6. Traumatic Knee dislocation.....	50
1.7.7. Patellar Dislocation.....	52
1.8. Surgical Infections.....	54
1.8.1. Septic Arthritis.....	54
1.8.2. Acute Osteomyelitis.....	57
1.8.3. Chronic Osteomyelitis.....	60
1.9. Hand Surgery.....	61
1.9.1. Fracture of Wrist Bones.....	61
1.9.2. Fracture of the Scaphoid Bone.....	61
1.9.3. Perilunate Dislocation and Perilunate Fracture Dislocation.....	63
1.9.4. Other Wrist Bone Fractures.....	64
1.9.5. Metacarpal Fractures.....	64
1.9.6. Bennett's and Rolando's Fractures.....	65
1.9.7. Boxer's Fracture.....	66
1.9.8. Fractures of Phalanges.....	67
1.9.9. Distal Phalanges and Nail Bed Injuries.....	68
1.9.10. Dislocations of the Hand Joints.....	69
1.9.11. Burns.....	70
1.9.12. Infections.....	70
1.9.13. Tendon Injuries.....	74
1.9.14. Nerve Injuries.....	75
1.9.15. Vessel Injuries.....	77
1.9.16. Skin Defects.....	78

2. Neurosurgery.....	79
2.1. Spinal Cord Injuries.....	79
2.1.1. General Considerations.....	79
2.1.2. Spinal Fractures and Dislocation.....	81
2.1.3. Subaxial Spinal Injuries (from C3 – C7).....	84
2.1.4. Spinal Cord Injury Without Radiographic Abnormality (SCIWORA).....	85
2.1.5. Thoracic Fractures.....	86
2.1.6. Thoracolumbar Fracture.....	87
2.1.7. Cauda Equina.....	90
2.2. Cerebral Vascular Diseases (Spontaneous Haemorrhage).....	91
2.2.1. Intracerebral Hemorrhage.....	91
2.2.2. Subarachnoid Hemorrhage.....	93
2.3. CNS Infections and Infestations.....	95
2.3.1. Brain Abscess.....	95
2.3.2. Cranial Subdural Empyema.....	96
2.3.3. Neuro Cysticercosis.....	97
2.4. Hydrocephalus in Children.....	98
2.5. Myelomeningocele.....	99
2.6. Head Injury.....	100
2.6.1. Acute Subdural Hematoma.....	104
2.6.2. Chronic Subdural Hematoma.....	104
2.6.3. Epidural Hematoma.....	105
2.6.4. Intracranial Hematoma.....	106
3. Cardio Thoracic Surgery.....	109
3.1. Chest Trauma.....	109
3.1.1. Simple Rib Fracture.....	109
3.1.2. Flail Chest.....	110
3.1.3. Pneumothorax.....	111
3.1.4. Haemothorax.....	112
3.1.5. Cardiac Tamponade.....	113
3.1.6. Lung Contusion.....	113
3.1.7. Ruptured Diaphragm.....	114

3.2 Lung Conditions.....	115
3.2.1. Empyema Thoracis.....	115
3.2.2. Lung Abscess.....	116
3.2.3. Pulmonary Fibrosis and Bronchectasis.....	117
3.2.4. Lung Cancer.....	118
3.2.5. Foreign Bodies in the Lung.....	119
3.3. Mediastinum Masses.....	120
3.4. Congenital Diaphragmatic Hernias.....	121
4. Abdominal Injuries.....	123
4.1. Specific Injuries.....	125
4.1.1. Splenic Injury.....	125
4.1.2. Hepatic Injury.....	125
4.1.3. Pancreatic Injury.....	126
4.1.4. Duodenal Injury.....	127
4.1.5. Small Bowel Injury.....	127
4.1.6. Colon Injury.....	128
4.1.7. Rectal Injury.....	128
5. Disorders of Gastro-Intestinal System.....	129
5.1. Disorders of the Oesophagus.....	129
5.1.1. Oesophageal Atresia.....	129
5.1.2. Achalasia.....	130
5.1.3. Gastroesophageal Reflux Disease.....	131
5.1.4. Esophageal Cancer.....	132
5.1.5. Esophageal Spasm.....	133
5.1.6. Perforation of Oesophagus.....	134
5.1.7. Hiatus Hernia.....	136
5.2. Acute Abdomen.....	137
5.3. Peritonitis.....	139
5.4. Intestinal Obstruction.....	141
5.4.1. Appendicitis.....	144
5.4.2. Appendiceal Mass and Abscess.....	145
5.4.3. Gall Stones.....	147
5.4.4. Acute Cholecystitis.....	148
5.4.5. Jaundice.....	149
5.4.6. Gastric Outlet Obstruction.....	151

6. Disorders of the Colon and Rectum.....	153
6.1. Colo-Rectal Cancer.....	153
6.2. Rectal Bleeding.....	154
6.3. Haemorrhoids.....	155
6.4. Perianal Abscess.....	156
6.5. Fistula in Ano.....	158
6.6. Carcinoma of Anus.....	159
6.7. Acute Pancreatitis.....	160
6.8. Chronic Pancreatitis.....	162
7. Genito-Urinary Disorders.....	163
7.1. Traumatic Disorders.....	163
7.1.1. Renal Injuries.....	163
7.1.2. Ureter Injury.....	164
7.1.3. Bladder Injury.....	165
7.1.4. Urethral Injury.....	166
7.1.5. Testicular Injury.....	166
7.2. Non Traumatic Disorders.....	167
7.2.1. Urinary Tract Infections (UTI).....	167
7.2.2. Hematuria.....	169
7.3. Testicular and Scrotal Disorders.....	170
7.3.1. Testicular Torsion.....	170
7.3.2. Fournier Gangrene.....	171
7.3.3. Testicular Cancer.....	172
7.3.4. Hydrocele.....	173
7.3.5. Undescended Testis.....	174
7.3.6. Varicocele.....	175
7.4. Disorders of the Penis.....	176
7.4.1. Priapism.....	176
7.4.2. Paraphimosis.....	177
7.4.3. Phymosis.....	177
7.4.4. Hypospadias.....	178
7.4.5. Carcinoma of the Penis.....	179
7.4.6. Impotence.....	180
7.5. Disorders of the Urethra.....	182
7.5.1. Urethra Meatal Stenosis.....	182

7.6. Disorders of the Prostate.....	183
7.6.1. Benign Prostatic Hyperplasia (BPH).....	183
7.6.2. Prostatic Cancer.....	184
7.7. Disorders of the Urinary Bladder.....	185
7.7.1. Bladder Calculi/Stones.....	185
7.7.2. Bladder Cancer.....	186
7.7.3. Cystocele.....	188
7.7.4. Urinary Incontinence.....	190
7.8. Disorders of the Kidney and the Ureter.....	192
7.8.1. Vesico-Ureteric Reflux.....	192
7.8.2. Calculus.....	193
7.8.3. Renal Cell Carcinoma.....	194
7.8.4. Nephroblastoma or Wilms Tumors.....	194
7.8.5. Pelvi-Ureteric Junctions.....	195
7.8.6. Tumors of the Renal Pelvis and Ureter.....	196
7.8.7. Urine Retention.....	197
7.8.8. Vesicovaginal Fistula.....	198
7.9. Neonatal Obstructive Uropathies.....	199
7.9.1. Posterior Urethral Valves.....	199
7.9.2. Urethral Stricture.....	200
7.10. Non Traumatic Urological Conditions.....	200
7.10.1. Benign Prostatic Hyperplasia (BPH).....	200
7.10.2. Adenocarcinoma.....	201
7.10.3. Bladder Cancer.....	202
7.10.4. Renal Cell Carcinoma.....	204
8. Burns.....	207
8.1. Electrical Burns.....	210
9. Bites and Stings of Animals and Insects.....	213
9.1. Animal Bites.....	213
9.2. Rabies.....	214
9.3. Snakebites and Venom.....	215
9.4. Insect Stings.....	220
9.5. Spider Bites.....	222
10. References.....	223
List of participants.....	227

Acronyms

ABG	: Arterial Blood Gas
AO	: Arterial Oxygen
ARDS	: Acute Respiratory Distress Syndrome
BPH	: Benign Prostatic Hyperplasia
CBC	: Complete Blood Count
CPK	: Creatine Phospho Kinase
CPP	: Cerebral Perfusion Pressure
CSF	: Cerebral Spinal Fluids
CT	: Computed Tomographic
CVP	: Central Venous Pressure
DCS	: Dynamic Compression Screws
DHS	: Dynamic Hip Screw
DRE	: Digital Rectal Exam
DRUJ	: Distal Radio-Ulna Joint
DRUJ	: Distal Radioulnar Joint
DVT	: Deep Venous Thrombosis
ECG	: Electrocardiogram
ERCP	: Endoscopic Retrograde Cholangio- Pancreatography
FBC	: Full Blood count
GA	: General Anesthesia
GIT	: Gastrointestinal Tract
GTN	: Glyceryl Trinitrate
HCL	: Hydrochloric
ICP	: Intra Cranial Pressure
ICU	: Intensive Care Unit
IVC	: Inferior Vena Cava
IVP	: Intra Venous Pressure
LC-DCP	: Limited Contact -Dynamic Compression Plate
LISS	: Less Invasive Stabilization
LMWH	: Low Molecular Weight Heparin
LoC	: Level of Consciousness
MIPO	: Minimally Invasive Plate Osteosynthesis
MRI	: Magnetic Resonance Imaging
NGT	: Naso-Gastric Tube
ORIF	: Open Reduction and Internal Fixation
PSA	: Prostate-Specific Antigen
PT	: Prothrombin Time
PTT	: Partial Thromboplastin Time

PUD	: Peptic Ulcer Disease
β HCG	: β Human Chorionic Gonadotropin
TARPO	: Retrograde Plate Osteosynthesis
TBSA	: Total Burn Surface Area
TIG	: Tetanus Immunoglobulin
TRUS	: Transrectal ultrasound
TURP	: Trans-Urethral resection prostate
UA	: Urinary Analysis
US	: Ultrasound
VF	: Vaginal Fistula
WBC	: White Blood cells

Foreword

The guidelines and protocols presented in this document are designed to provide a useful resource for healthcare professionals involved in clinical case management in Rwanda. They were developed by taking into consideration services provided at different levels within the health system and the resources available, and are intended to standardize care at both the secondary and tertiary levels of service delivery across different socio-economic levels of our society.


The clinical conditions included in this manual were selected based on facility reports of high volume and high risk conditions treated in each specialty area. The guidelines were developed through extensive consultative work sessions, which included health experts and clinicians from different specialties. The working group brought together current evidence-based knowledge in an effort to provide the highest quality of healthcare to the public. It is my strong hope that the use of these guidelines will greatly contribute to improved the diagnosis, management, and treatment of patients across Rwanda. And it is my sincere expectation that service providers will adhere to these guidelines and protocols.

The Ministry of Health is grateful for the efforts of all those who contributed in various ways to the development, review, and validation of the Clinical Treatment Guidelines. We would like to thank our colleagues from District, Referral, and University Teaching Hospitals, and specialized departments within the Ministry of Health, our development partners, and private health practitioners. We also thank the Rwanda Professional Societies in their relevant areas of specialty for their contributions and for their technical review, which enriched the content of this document, as well as the World Health Organization (WHO) and the Belgium Technical Cooperation (BTC) for their support.

We would like to especially thank the United States Agency for International Development (USAID) for both their financial and technical support through the Management Sciences for Health (MSH) Integrated Health System Strengthening Project (IHSSP) and Systems for Improved Access to Pharmaceuticals and Services (SIAPS).

To end with, we wish to express our sincere gratitude to all those who continue to contribute to improving the quality of health care of the Rwanda population.

Dr Agnes Binagwaho
Minister of Health



1. Orthopaedic Surgery

GENERAL OVERVIEW OF FRACTURES

Definition: A fracture is a complete or non-complete disruption of continuity of the bone tissue. Fractures can be classified as open or closed fractures, and multi-fragmented or simple and displaced or undisplaced.

Causes

- High energy trauma
- Motor vehicle accidents
- Sports injuries
- Fall from height
- Low energy trauma
- Simple fall
- Medical conditions

Signs and symptoms

- Pain
- Swelling
- Wounds
- Deformity
- Tenderness
- Inability to move
- Possibility of neurovascular deficit

General Investigations

- Blood tests: Full Blood Count, Blood Group, PT, PTT and specific tests depending on patient condition and past medical history
- X-ray
- Ultrasound, CT-Scan, MRI as indicated

General management of fractures

- Assessment consists of four overlapping phases namely:
- Primary survey (ABCDE)
- Resuscitation
- Secondary survey
- Definitive care

Primary survey (ABCDE) and resuscitation

- This process identifies and treats life-threatening conditions as per ATLS (Advanced Trauma Life Support) protocols:
 - Airway maintenance (with cervical spine protection)
 - The airways should be rapidly assessed for signs of obstruction, foreign bodies and facial, mandibular, or tracheal/laryngeal fractures. A chin lift or jaw thrust manoeuvre should be used to establish an airway
 - Breathing and ventilation

Any four of the following conditions if present, should be addressed as an emergency

- Tension pneumothorax
- Flail chest
- Pulmonary contusion
- Open pneumothorax
- Massive hemothorax
- Cardiac tamponade
- Circulation (with hemorrhage control), monitor vital signs:
 - Blood Pressure
 - Pulse Rate
 - Heart Rate
 - Respiratory Rate
 - Oxygen saturation

Secondary survey (history and head-to-toe evaluation)

- Identify life threatening injuries using the Glasgow Coma Scale:
 - Alert and oriented
 - Vocal stimuli
 - Painful stimuli
 - Unresponsive
- A Glasgow Coma Scale of 8 or less is an indication for the placement of a definitive airway (e.g. intubation). If patient has tension pneumothorax, flail chest, pulmonary contusion, open pneumothorax, massive hemothorax, cardiac tamponade must be addressed as emergencies.
 - Abdomen (Refer to abdominal trauma management)
 - Spine (Refer to spine injury management)
 - Disability: Exposure of the whole body, ensure environmental safety and avoid hypothermia
 - Complete examination of skeletal, soft tissue injuries and distal neurovascular status

- Open injuries evaluation
- Definitive care
- An open fracture is when disruption of the skin and underlying soft tissue results in communication between the fracture and the outside environment.

Severity assessment (Gustilo-Anderson classification)

- *Grade I:* The wound is less than 1cm long. It is usually a moderately clean puncture (from inside-out).
- *Grade II:* The laceration is more than 1 cm long, and there is no extensive soft-tissue damage. There is a slight or moderate crushing injury, moderate comminution of the fracture, and moderate contamination.
- *Grade III:* These are characterized by extensive damage to soft-tissues, including muscles, skin, and neurovascular structures, and a high degree of contamination (Bone is exposed).
 - *III A:* Bone is exposed but there is no periosteal stripping
 - *III B:* Bone is exposed but there is periosteal stripping
 - *III C:* There is association of vascular injury that requires repair

Management

- Initial management
- Adequate wound care and immobilization
- Drugs therapy (VAT, SAT, analgesics, antibiotics)
- DVT prophylaxis if indicated
- Antibiotic: The choice of antibiotic to be used depends on the Fracture type and the likely contamination of the fracture site.
- Grade 1: 1st generation cephalosporin
- Grade 2: 1st generation cephalosporin + or – an aminoglycoside depending on the level of wound contamination.
- Grade 3: 1st generation cephalosporin and an aminoglycoside
- All forms of injuries are treated as Grade 3 with addition of penicillin to cover for staphylococcal infection

Surgical debridement and irrigation

- Surgical debridement should be done in theatre after thorough washing of the wound
- Debridement has been suggested to be done within 6 hours of injury

Note: For gustillo type III: External fixation is the golden standard form of fracture fixation and stabilisation

SPECIFIC FRACTURES

1.1. Upper Limb Fractures

1.1.1. Distal Radius & Ulna Fractures

Fracture Classification

No one fracture classification system is comprehensive in describing all important variables of distal radius fractures. Based on AO classification, distal radius fractures are divided into three groups:

- *Type A*: Extraarticular
- *Type B*: Partial articular
- *Type C*: Complete articular

Management

Aim

- To achieve anatomical reduction

Anatomical Criteria of reduction: AP and lateral x- ray views

- Radial inclination 20-23 degrees,
- Volar tilt 11 degrees to 12 degrees
- Radial styloid length should be 1,5cm distal to ulnar styloid

Extraarticular nondisplaced fractures

- Cast immobilization for 4-6 weeks, followed by rehabilitation

Extraarticular displaced fractures

- Non-operative treatment
- Closed reduction and immobilization
- Operative treatment is advocated if the reduction cannot be achieved or maintained by closed means

Means of fracture fixation

- Pins (k-wires)
- Plates and screws
- External fixators

Intraarticular fractures (AO Type B and C)

- The treatment of intraarticular fractures aims at restoring the congruity of the articular surface which can be done by:
- Closed (pins and cast, external fixators)
- Open means (plates and screws)

1.1.2. Forearm Shaft Fractures

Definition: It is a disruption of the bone continuity located between the distal and proximal epiphysis.

Isolated fracture of the Ulna, it is a disruption of the bone continuity located between the distal and proximal epiphysis.

Management

- Nondisplaced or minimal displacement:
 - Long arm cast immobilization for 6 weeks
 - Cast removal is followed by physiotherapy
 - The time to union is about 3 months
- Displaced fractures (angulation > 10 degrees or displacement > 50%):
 - Open reduction and internal fixation with a 3.5 mm plate
 - Alternative implants: locked nail, flexible nail
- Isolated radial shaft fracture

Management

- Nondisplaced or minimal displacement
 - Long arm cast immobilization for 6 weeks
 - Cast removal followed by physiotherapy
 - The time to union is about 3 months
- Displaced fractures (angulation > 10 degrees or displacement > 50%)
 - Open reduction and internal fixation with a 3.5 mm plate
 - Alternative implants: locked nail, flexible nail
- Galeazzi fracture
 - It is a fracture of the radial diaphysis at the junction of the middle and distal thirds with disruption of the distal radio-ulna joint (DRUJ)

Management

- Open reduction through a Volar Henry approach and internal fixation with plate fixation
- Distal radioulna joint examination
- DRUJ stable: immobilization in neutral /supination position (6 weeks)
- DRUJ unstable: pinning in a position of stability
- Dislocated and irreducible DRUJ: open stabilization with repair of associated ligaments
- Monteggia Fracture

It is a fracture of proximal ulna associated with anterior radial head dislocation

Management

- Children
 - Closed reduction and immobilization
- Adult
 - open reduction and internal fixation of the ulna plus closed reduction of the radial head, followed by immobilization for 3 weeks

Note:

- If closed reduction is not achievable, open reduction is required. Attention should be paid to the relationship between the annular ligament, the lateral epicondyle, and the radial head.
- Entrapment of the soft tissues is the most common reason for inability to obtain concomitant closed radial head reduction at the time of open reduction and internal fixation of the ulna.
- Fractures of both the Radius & Ulna, are usually the result of high-energy injuries. These fractures are usually displaced because of the force required to produce such an injury

Management*Undisplaced fracture (VERY RARE)*

- Immobilization with long arm cast for 6 weeks with early digital active and passive motion exercises.

Displaced fracture

- Open reduction and internal fixation with plate.
(Alternative implants: intramedullary nails, flexible nails, pins)

Note: Bone grafting can be used for severely comminuted fractures with significant bone loss.

1.1.3. Distal Humerus Fractures

INTERCONDYLAR FRACTURES

Classification (Rise-borough and Radin)

There are four types namely

- Type I: Undisplaced fracture between the capitellum and trochlea
- Type II: Separation of the capitellum and trochlea without appreciable rotation of fragments in the frontal plane
- Type III: Separation of the fragments with rotator deformity
- Type IV: Severe comminution of the articular surface with wide separation of the humeral condyle

Management

- Type I: Conservative treatment
- Type II & III: Open Reduction and Internal Fixation (ORIF)
- Type IV: Young patients: Bone reconstruction and grafting of articular defects
- Elderly patients (osteopenic bone): Transolecranon traction or total elbow arthroplasty

FRACTURE OF THE EPICONDYLES

- Treatment depends on the amount of displacement
 - If displacement is minimal, then closed reduction is appropriate
 - A displaced fracture may require open reduction and screw fixation

OLECRANON FRACTURES

Fracture of the olecranon commonly occurs with a direct blow or as an avulsion injury with triceps contracture.

Management

- None displaced fractures, or fractures with <2 mm displacement: immobilization with the elbow in 45-90 degrees of flexion for 3 weeks (7-10 days in back slab and 2 weeks with a long arm cast).
- Displaced fractures: ORIF
 - The optimal method for treating this fracture is tension banding with two longitudinal K-wires placed across the fracture site and stabilized with a figure-of-8 wire loop
 - More oblique fractures can be treated with interfragmentary screws with a neutralization plate
 - If the articular surface is significantly comminuted, a low-profile, limited contact compression plate can be applied to the dorsal surface of the ulna

All these treatments can generally be accompanied with early protected range-of-motion exercises.

FRACTURE OF THE RADIAL HEAD

Radial head fractures are generally caused by longitudinal loading from a fall on an outstretched hand; dislocation of the elbow is another cause.

Classification

- Mason proposed a classification scheme for radial head fractures
 - Type I is a nondisplaced fracture
 - Type II is a fracture that is displaced usually involving a single large fragment
 - Type III is a comminuted fracture
 - Type IV is a fracture associated with an elbow dislocation

Management

- Type I: Non-operative treatment with early motion
- Type II:
 - Displacement less than 2 mm step-off : non surgical treatment
 - Displacement more than 2mm step-off: ORIF; open reduction and internal fixation can be performed with pins or articular screws

- Type III: Early radial head excision/arthroplasty
- Type IV: Reduction of elbow dislocation and excision if comminuted fracture/retain and fix radial head if no comminution

CAPITELLAR FRACTURES

Classification

- Type I: *Hahn-Steinthal I*: Osteochondral injury or complete fracture
- Type II: *Kocher-Lorenz*: Articular-cartilage-only injury
- Type III: *Hahn-Steinthal II*: Comminuted fracture or a fracture line extending into the trochlea. CT reconstructions are useful to further delineate the fracture and for surgical planning.

Management

- Open reduction and internal fixation with K-wire or articular screws

1.1.4. Humeral Shaft Fracture

Management

Non-operative methods

- Cast immobilization (shoulder spica, U-slab, Sarmiento cylinder cast etc.) leads to good results with high union rates.

Operative treatment

- Special circumstances may merit open reduction and fixation
 - Selected segmental fractures
 - Inadequate closed reduction
 - Floating elbow
 - Bilateral humeral fractures
 - Open fractures
 - Multiple trauma
 - Pathologic fractures
 - Humerus fracture with associated vascular injuries requiring exploration may benefit from internal fixation
- There are two general forms of internal fixation namely
 - Compression plate and screw fixation
 - Intramedullary nailing: especially useful in osteopenic bone, segmental and external fixator if contaminated open fractures

Note: Be aware of radial nerve injury

1.1.5. Fractures of Proximal Humerus

Classification (Duparc and Neer)

Fractures are classified by the number of parts that are displaced more than 1 cm or angulated more than 45 degrees.

- Two part fractures
 - Anatomic neck fracture
 - Tuberosity fracture
 - Surgical neck fracture
- Three part fractures
- Four part fractures

Management

Non displaced fractures (85%)

- Non-operative treatment with an arm sling or shoulder immobilizer
- Early mobilization

Displaced fractures: operative treatment

- Two part fractures with anatomic neck fractures:
 - Young patients: ORIF (pins /screws)
 - Elderly patients: Hemi-arthroplasty

Note:

- Closed reduction is difficult because of controlling the articular fragment
- High risk of avascular necrosis of the humeral head

1.1.6. Tuberosity Fractures

GREATER TUBEROSITY

- Attempt closed reduction and immobilization
- If irreducible fracture: ORIF (pins /screws)
- If associated with shoulder dislocation:
 - Simple reduction of the dislocation may reduce the tuberosity fracture
 - If not: ORIF

LESSER TUBEROSITY

- If small fragment, closed reduction
- If larger fragments: ORIF

SURGICAL NECK FRACTURE

- Impacted fracture with < 450 angulation : Sling immobilization plus early mobilization
- Displaced, unstable, or fracture >450 angulation:
 - Closed Reduction and percutaneous pinning or intramedullar pinning under fluoroscopic control
 - If the closed reduction fails: ORIF (plates and screws)

THREE PARTS FRACTURES

- Open reduction and internal fixation (plates and screws)
- Hemiarthroplasty should be considered in the elderly

FOUR PART FRACTURES

- Open reduction and internal fixation
- Hemiarthroplasty in elderly, particularly because the avascular necrosis rate may be as high as 90% and the bone is usually osteoporotic
- Repair of any rotator cuff defects is necessary to prevent proximal migration of the humeral component as well as loss of rotator cuff power
- Early post-operative rehabilitation

1.1.7. Clavicle Fractures

Classification (Allman)

- Type I: Fracture of the middle third (80%)
- Type II: Fracture of the distal third (15%)
- Type III: Medial clavicle fractures (close to the sternum) (5%)

Management

- Non-operative treatment (arm sling, figure-of-eight brace or universal shoulder immobilizer)

Indications of operative treatment (ORIF)

- Clavicle fracture associated with neurovascular injury
- Floating shoulder
- Open fracture
- Bilateral clavicle fractures
- Threatened underlying skin

1.1.8. Scapula Fractures

Classification (AO/OTA)

- Type A: Extraarticular
- Type B: Body of scapula fracture
- Type C: Intraarticular glenoid fracture

Management

Non-operative treatments

- Sling use and early range of motion

Operative treatment indication

- Displaced intraarticular fracture involving more than 25% of the articular surface
- Scapula neck fracture with greater than 40° angulation or 1cm medial translation
- Scapula neck fracture with associated displaced clavicle fracture
- Fracture of the acromion that impinge on the subacromial space
- Fracture of the coracoid process that result in a functional acromio-clavicular separation
- Comminuted fracture of the scapula spine

1.2. Pelvic and lower limbs fractures

1.2.1. Pelvic Ring Disruption

Classification (Tile)

Clinical and radiological evaluation of the pelvis based on identification of the grade of stability or instability, this is the platform for further decision-making.

- Type A: Stable pelvic ring injury (50-70%)
 - A1: Avulsion of the innominate bone
 - A2: Stable iliac wing fracture or stable minimally displaced ring fractures
 - A3: Transverse fractures of the sacrum and the coccyx

- Type B: Partially stable (20-30%) rotationally unstable, vertically stable
 - B1: Open book injury
 - B2: The lateral compression injury
 - B3: Bilateral B injuries

- Type C: Unstable (10-20%) both rotationally and vertically unstable
 - C1: Unilateral
 - C2: Bilateral, one side B one side C
 - C3: Bilateral C lesions

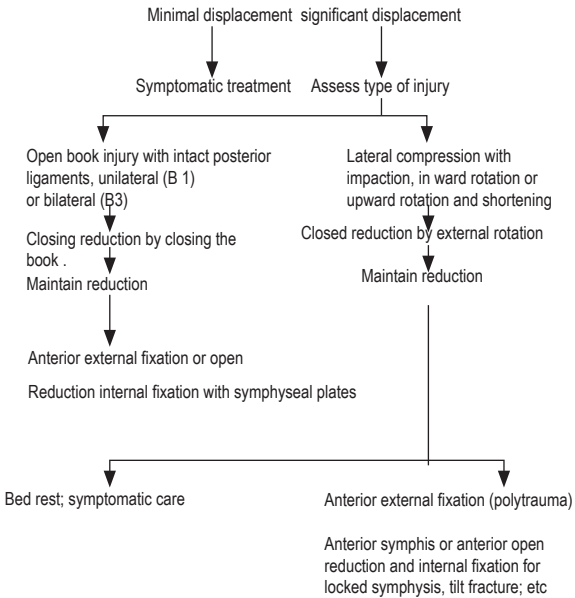
Management

After rapid resuscitation, complete assessment of the personality of the injury including stability of the ring. The decision on whether or not to operate can be based on the fracture types:

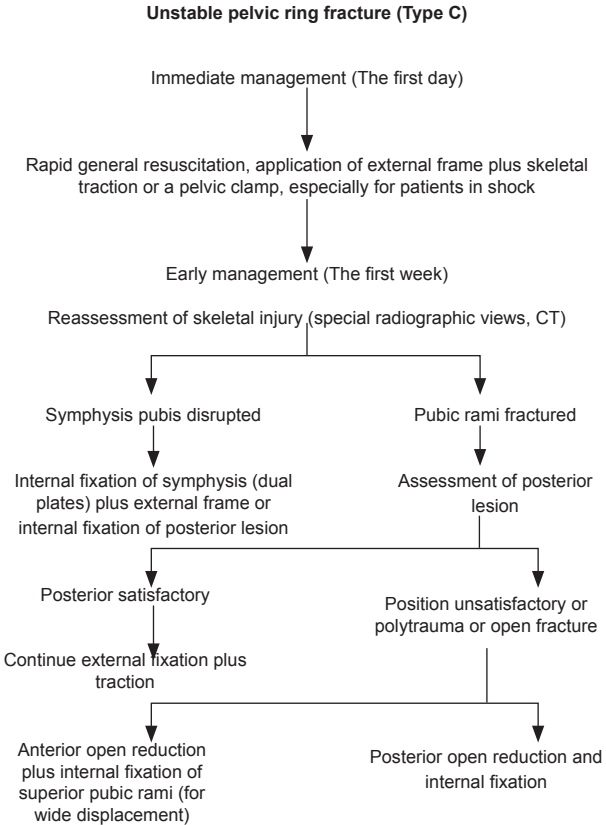
PELVIC RING STABLE (TYPE A OR B)

After rapid resuscitation, assess of personality of injury including stability of the ring

PELVIC RING STABLE (Type A or B)



PELVIC RING UNSTABLE (TYPE C)



1.2.2. Fractures of the Acetabulum

Classification (Letournel)

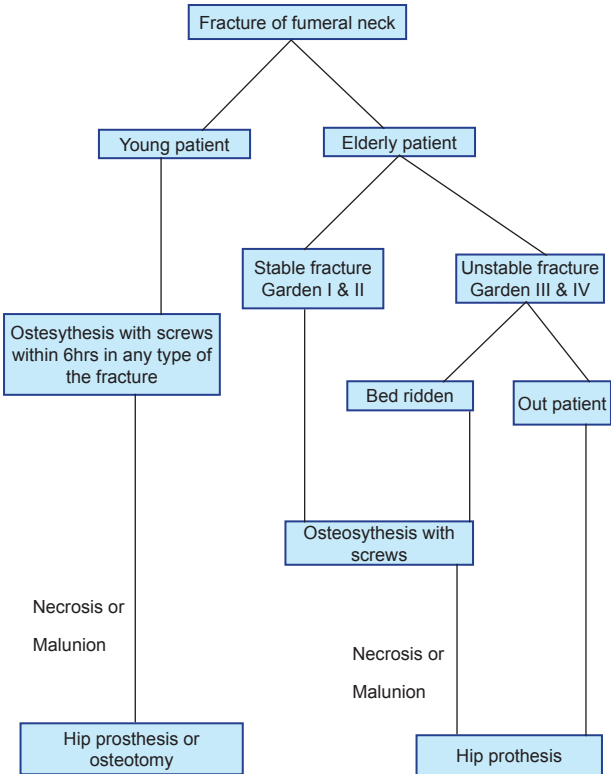
- Type A: Partial articular fractures, one column involved
 - A1: posterior wall fracture
 - A2: posterior column fracture
 - A3: anterior wall or anterior column fracture

- Type B : Partial articular fractures (transverse or T type fracture, both columns involved)
 - B1: transverse fracture
 - B2: T-shaped fracture
 - B3: anterior column plus posterior hemitransverse fracture

- Type C: Complete articular fracture (both column fracture, floating acetabulum)
 - C1: Both column fracture, high variety
 - C2: Both column fracture, low variety
 - C3: Both column fracture involving the sacro-iliac joint

Management

The goal of treatment is to attain a spherical congruency between the femoral head and the weight-bearing acetabular dome, and to maintain it until bones are healed.



1.2.3. Trochanteric Fractures

ISOLATED LESSER TROCHANTER FRACTURE: (RARE)

A symptomatic non-union may require fragment fixation or excision.

ISOLATED GREATER TROCHANTER FRACTURE

Management

- Displacement less than 1 cm and no tendency toward further displacement:
 - Bed rest until acute pain subsides
 - Activity can increase gradually to protected weight bearing with crutches
 - Full weight bearing is permitted as soon as healing is apparent, usually in 6–8 weeks
- Displacement greater than 1 cm and increases on adduction of the thigh: ORIF

INTERTROCHANTERIC FRACTURES

These fractures usually occur along a line between the greater and the lesser trochanter.

Classification (Boyd & Griffin)

- Type I: A single fracture along the intertrochanteric line
- Type II: Intertrochanteric line fractures with comminution
- Type III: Fracture at the level of the lesser trochanter with variable comminution and extension into the subtrochanteric region (reverse obliquity)
- Type IV: Fracture extending into the proximal femoral shaft

Management

Initial treatment

- Skin traction to minimize pain and further displacement

Definitive treatment

- Depends upon the general condition of the patient and the fracture pattern
- Operative treatment within 48 hours is preferred
- Reduction and internal fixation with sliding hip screw (DHS, RSP etc.)
- The patient can be taken out of bed the next day
- Weight bearing with crutches or a walker is begun as soon as pain allows

- The fracture usually heals in 6–12 weeks

Alternatives

- Second-generation interlocked nails (PFN, IMHS, Gamma nails etc.)

SUBTROCHANTERIC FRACTURES

Classification (Russell & Taylor)

- Type IA
 - Fractures do not involve the piriformis fossa
 - Lesser trochanter attached to the proximal fragment
- Type IB
 - Fractures do not involve the piriformis fossa
 - Lesser trochanter is detached from the proximal fragment
- Type II: Fractures have fracture extension into the piriformis fossa

Management

- Type I: ORIF with cephalo-medullary nail (“gamma nails,” intramedullary hip screws, PFN, Russel-Taylor and Trigen reconstruction nails etc.)
- Type II: Is best treated with a sliding hip screw or fixed angle plate

1.2.4. Femoral Neck Fractures

Classification (Garden)

- Type 1: Valgus impaction of the femoral head
- Type 2: Complete but non displaced
- Type 3: Complete fracture, displaced less than 50%
- Type 4: Complete fracture displaced greater than 50%

This classification is of prognostic value for the incidence of avascular necrosis: The higher the Garden number, the higher the incidence

Management

Initial treatment

- Traction may offer comfort in some patients but do not improve overall outcome

Definitive treatment

- Internal fixation

1.2.5. Femoral Shaft Fractures

Classification (Winquist)

- Type 1: Fracture that involves no, or minimal, comminution at the fracture site, and does not affect stability after intramedullary nailing
- Type 2: Fracture with comminution leaving at least 50% of the circumference of the two major fragments intact
- Type 3: Fracture with comminution of 50–100% of the circumference of the major fragments.
- Type 4: Fracture with completely comminuted segmental pattern with no intrinsic stability

Management

Treatment depends upon the age and medical status of the patient as well as the site and configuration of the fracture.

Conservative Treatment

- Is rarely indicated

Operative Treatment

- Interlocking intramedullary nailing is the Golden standard treatment of femoral shaft fracture

Alternative Treatment

- Non locked intramedullary nails (Kuntscher nail, flexible nails, AO nails etc.), do not provide ideal stable fixation
- Plates and screws: require significant soft-tissue dissection and opening of the fracture hematoma and can be associated with high rate of infection.
- External fixation: remains indicated in some open fractures and in polytrauma patients

1.2.6. Distal Femur Fractures

These fractures involve the distal metaphysis and epiphysis of the femur.

Classification (AO/OTA)

- Type A: Extraarticular
 - A1: Simple fracture
 - A2: Metaphyseal wedge fracture
 - A3: Metaphyseal complex fracture
- Type B: Unicondylar partial articular
 - B1: Lateral condylar fracture

- B2: Medial condylar fracture
- B3: Frontal fracture
- Type C : Intercondylar/ bicondylar, complete articular
 - C1: Articular simple, metaphyseal simple
 - C2: Articular simple, metaphyseal complex
 - C3: Multifragmentary articular fracture

Management

EXTRAARTICULAR FRACTURES

Conservative treatment

- Skeletal traction treatment is reserved for patients for whom surgery is not possible due to comorbidities

Operative treatment

- Retrograde intramedullary nailing
- Plates and screws (blade plates, locking plates, sliding plates)
- External fixator (Ilizarov frame etc.)

INTRAARTICULAR FRACTURES

- Maximal functional recovery of the knee joint requires anatomic reduction of the articular components and restitution of the mechanical axis
- Undisplaced intraarticular fractures: cast immobilization(6-8 weeks)
- Displaced intraarticular fractures usually require open reduction and internal fixation with a variety of methods including:
 - Dynamic Compression Screws (DCS)
 - Plates and screws

1.2.7. Patellar Injuries

TRANSVERSE PATELLAR FRACTURE

Transverse fractures of the patella are the result of indirect force, usually with the knee in flexion.

Management

Non displaced fractures

- Walking cylinder cast or brace for 6–8 weeks followed by knee rehabilitation.

Displaced fractures

- Open reduction and immobilization by figure-of-eight tension banding over two longitudinal parallel K-wires.

- If the minor fragment is small (no more than 1 cm in length) or severely comminuted, it may be excised and the quadriceps or patellar tendon (depending upon which pole of the patella is involved) sutured directly to the major fragment.

COMMINUTED PATELLA FRACTURE

Comminuted fractures of the patella are usually caused by a direct force.

Management

Undisplaced or minimally displaced/ too comminuted to be fixed

- Conservative treatment by cylinder cast immobilization for 6-8 weeks

Severe displacement

- Operative treatment by tension band wiring
- Alternative: excision of the patella and repair of the defect by imbrication of the quadriceps expansion

1.2.8. Proximal Tibia Fractures

TIBIAL PLATEAU FRACTURES

Classification (Schatzker)

- Type I: split fracture of the lateral plateau
- Type II: split-depression of the lateral plateau
- Type III: depression of the lateral plateau
- Type IV: medial plateau fracture
- Type V: bicondylar fracture
- Type VI: plateau fracture with metaphyseal-diaphyseal dissociation

Management

Conservative treatment: Cast immobilization

- Articular step-off of 3 mm or less and condylar widening of 5 mm or less can be treated conservatively
- Lateral or valgus tilt up to 5 degrees is well tolerated

Operative treatment

- Medial plateau fractures with any significant displacement.
- Articular step-off >3 mm
- Bicondylar fractures with any medial displacement, valgus tilt >5 degrees or with significant articular step-off

Minimal invasive treatment

- Closed reduction under fluoroscopy plus percutaneous pinning/screws
- Minimally Invasive Plate Osteosynthesis (MIPO) and the Less Invasive Stabilization Systems (LISS) are used in the treatment of these injuries

Open reduction: ORIF with plates and screws

External fixation

- Monolateral or ring fixator
- Hybrid-Ring external fixators

Recommendations

- Bone defects should be grafted
- Early range of motion with weight bearing is allowed at 6–8 weeks

1.2.9. Tibia-Fibula Fractures

The Tibia has a subcutaneous anteromedial border and is bound to be associated with significant soft tissue injury.

Classification (Tscherne and Oestern): classified as soft tissue injury in ascending order of severity

- Grade 0: Soft-tissue damage is absent or negligible.
- Grade 1: There is a superficial abrasion or contusion caused by fragment pressure from within.
- Grade 2: A deep contaminated abrasion is present associated with localized skin or muscle contusion from direct trauma. Impending Compartment Syndrome is included in this category.
- Grade 3: The skin is extensively contused or crushed and muscular damage may be severe. Also, Compartment Syndrome and rupture of a major blood vessel may be present.

Isolated Fibula Diaphysis Fractures: The isolated fibular fracture usually heals independently of the form of treatment.

- **Isolated Tibia Diaphyseal Fractures:** There is a tendency for the tibia to displace into varus angulation because of an intact fibula
- Fractures of both the tibia and fibula

Criteria for reduction of a tibial shaft fracture in adults

- Apposition of 50% or more of the diameter of the bone in both anteroposterior and lateral projections
- Not more than 5 degrees of varus or valgus angulation

- Not more than 5 degrees of angulation in the anteroposterior plane
- Not more than 10 degrees of rotation
- Not more than 1 cm of shortening

Management

The goal of treatment is to allow the fracture to heal in an acceptable position with minimal negative effect on the surrounding tissues or joints

Undisplaced fractures

- Conservative treatment with a long leg cast

Displaced fractures

- Reduction in emergency room
- If acceptable and stable: long leg non-weight-bearing cast (6-8 weeks). At 6 weeks, some shaft fractures are stable enough to be put in a short leg weight-bearing cast (Sarmiento).
- If unacceptable or unstable reduction: attempt reduction under anesthesia
- Reduction under anesthesia
- If acceptable and stable: long leg non-weight-bearing cast (6-8 weeks). At 6 weeks, some shaft fractures are stable enough to be put in a short leg weight-bearing cast (Sarmiento).
- If unsuccessful reduction by closed means: operative treatment
- Operative treatment
- Intramedullary nailing (best with interlocking devices)
- Alternative: plates and screws

1.2.10. Fractures of the Distal end of the Tibia

Also referred to as **pilon** or **plafond** fractures, these fractures involve the distal articular surface of the tibia, the tibiotalar joint and usually the shaft of the fibula.

Classification (Ruedi and Allgower):

- Type I: non displaced fracture with non significant articular incongruity
- Type II: articular displacement less than 5mm
- Type III: Displaced and comminuted fracture with significant articular comminution

Management

The goal of treatment is to restore an anatomic articular surface. This can be difficult and sometimes impossible. Bone graft can be added to metaphyseal defects to support the articular surface

Type I:

- Long leg cast and leg elevation

Type II

- ORIF of the fibula
- ORIF of the tibia. Once soft-tissue swelling subsides, minimally invasive open reduction and percutaneous techniques should be attempted.

Type III

- ORIF of the fibular fracture to restore length
 - ORIF of the tibia
 - Closed reduction and external fixation of the tibia
 - Combination of ORIF and external fixation of the tibia
- If risk of over swelling
- Prevention or treatment of swelling by prolonged leg elevation
 - Open surgical treatment should be deferred until the soft tissue condition improves (7-14 days)
 - Weight bearing if there is radiologic evidence of bone healing

1.3. Foot Fractures

1.3.1. Ankle Fractures

Classification (Weber)

- Type A
 - Avulsion of the fibula to the joint line
 - Syndesmotomic ligament intact
 - Medial malleolus undamaged or fractured in a shear –type pattern with the fracture line angulating in a proximal-medial direction from the corner of the mortis:
 - Oblique or Oblique or spiral fraala beginning fibula beginning at the level of the joint up to the shaft of the fibula.
 - The syndesmotomic ligament complex can be torn, but the large interosseous ligament is usually left intact so that no widening of the distal tibiofibular articulation occurs.

- Medial malleolus intact or sustain a transverse avulsion fracture. If the medial malleolus is left intact there can be a tear of the deltoid ligament.
 - Posterior malleolar avulsion fracture can also occur.
- Type B
- Fracture of the fibula proximal to the syndesmotic ligament complex
 - Disruption of the syndesmosis
 - Medial malleolar avulsion fracture or deltoid ligament rupture
 - Posterior malleolar avulsion fracture can also occur

Note:

Fracture of the medial malleolus with complete disruption of the syndesmosis and a proximal fibular shaft fracture (Maisonneuve's fracture) are also considered bimalleolar fractures on a functional basis.

Management

Principles of initial treatment of ankle fractures

- Immediate closed reduction and splinting, with the joint held in the most normal position possible to prevent neurovascular compromise of the foot.
- An ankle joint should never be left in a dislocated position.
- If the fracture is open, the patient should be given appropriate intravenous antibiotics and taken to the operating room on an urgent basis for irrigation and debridement of the wound, fracture site, and ankle joint. The fracture should also be appropriately stabilized at this time.

Conservative treatment: well-molded short leg cast for 6 weeks.

Indications for non operative treatment include

- Non displaced stable fracture patterns with an intact syndesmosis
- Displaced fractures for which stable anatomic reduction is achieved
- An unstable or multiple trauma patient in whom operative treatment is contra-indicated due to the conditions of the patient or the limb
- Operative treatment: ORIF and well-molded short leg cast for 6 weeks.

ORIF is indicated if

- Failure to achieve or to maintain closed reduction
- Displaced or unstable fractures
- Fractures that requires abnormal foot positioning to maintain reduction

TRIMALLEOLAR FRACTURES

After the lateral and medial malleolar fractures have been internally fixed, ligamentotaxis often will anatomically reduce the posterior malleolar fragment. If this fragment represents less than 25% of the articular surface of the tibial plafond and there is less than 2 mm of displacement, internal fixation is not always required.

1.3.2. Calcaneus Fractures

Classification (Essex-Lopresti): Classification based on radiologic images

- Type I: extraarticular fractures
 - Anterior process fracture
 - Tuberosity fracture
 - Medial process fracture
 - Sustentacular fracture
 - Body fracture
- Type II: Intraarticular fractures
 - Depression type
 - Tongue type
 - Comminuted

Classification (Sanders): *Classification based upon coronal CT- scan images*

- Type I: All non displaced fractures regardless of the number of fracture lines
- Type II: Fractures are two-part fractures of the posterior facet and are divided into A, B, and C based upon the location of the fracture line
- Type III: Fractures are three-part fractures with a centrally depressed fragment, also divided into A, B, and C
- Type IV: Fractures are four-part articular fractures with extensive comminution

Management

Extraarticular Fractures

- Fracture of the Anterior Process
 - Treatment is by a non-weight-bearing short leg cast in neutral position for 4 weeks
- Fracture of the Tuberosity
 - Isolated fractures of the calcaneal tuberosity are rare.
- Horizontal Fracture
 - If the fragment is big enough, the application of the skeletal traction can reduce it to the plantar-flexed foot, and the pin is incorporated in a long leg cast with the knee flexed at 30 degrees. For smaller fragments or when closed reduction is unsuccessful, ORIF with screws, wires or pullout sutures is indicated.
- Vertical Fracture
 - Because the minor medial fragment normally is not widely displaced, plaster immobilization is not required but may reduce pain. Limitation of weight bearing with crutches is helpful.
- Fracture of the Medial Process:
 - Conservative treatment with a well-molded short leg walking cast is usually successful
- Fracture of the Body
 - Marked displacement may benefit from closed reduction to improve heel contour
- Fracture of the Sustentaculum
 - Conservative treatment is usually successful. In the rare instance of symptomatic non-union, careful excision is indicated
- Intra-articular fractures
 - Treatment of displaced intraarticular fractures remains controversial
 - Some surgeons still advise conservative treatment
 - Other surgeons advocate early closed manipulation of displaced intra-articular fractures, to at least partially restore the external anatomic configuration of the heel region. Internal fixation with percutaneous pins (Essex-Lopresti technique) may be performed.

- Open reduction and internal fixation with pins, screws, or plates, with or without bone grafting, has gained acceptance. The aim of ORIF is to restore Böhler's angle and improve heel alignment through stable fixation.
- Some authors advocate primary subtalar arthrodesis for severely comminuted fractures.

1.3.3. Talus Fractures

Three fifths of the talus is covered with articular cartilage. The blood supply enters the neck area and is tenuous. Fractures and dislocations may disrupt this vascularization, causing delayed healing or avascular necrosis.

FRACTURES OF THE NECK OF THE TALUS

Hawkins classification

- Type 1: Nondisplaced vertical fracture
- Type 2: Displaced fracture of the talar neck with subluxation or dislocation of the subtalar joint
- Type 3: Displaced fracture of the talar neck with dislocation of the body of the talus from both the tibiotalar and subtalar joints
- Type 4: Later, a type 4 fracture was described by Canale and Kelly to include rare variants which are essentially type 3 injuries with talonavicular subluxation or dislocation.

Management

Type 1

- Non-weight-bearing below-knee cast for 2–3 months until clinical and radiologic signs of healing are present

Type 2

- Closed reduction. In about 50% of cases, closed reduction is unsuccessful and open reduction and internal fixation with K-wires, pins, or screws is indicated

Types 3 and 4

- Closed reduction is almost never successful; ORIF is the rule.

FRACTURES OF THE BODY OF THE TALUS

Hawkins classification

- Type 1: Osteochondral fracture
- Type 2: Coronal, sagittal or horizontal fracture
- Type 3: Posterior process fracture
- Type 4: Lateral process fracture
- Type 5: Crush fracture of the body

Management

- Undisplaced and minimally displaced fractures; do conservative treatment
- Significant displaced fractures:
 - Closed reduction and short leg cast with foot in plantar flexion
 - If closed reduction is not successful then open reduction

OSTEOCHONDRAL FRACTURES OF THE TALAR DOME

Berndt and Harty classification

- Stage 1: Localized compression
- Stage 2: Incomplete separation of the fragment
- Stage 3: Completely detached but non displaced fragment
- Stage 4: Completely detached, displaced fracture

Management

- Stage 1, 2, and 3: Immobilization and restricted weight bearing.
- Stage 4 and failed conservative treatment stage 1,2,3: Reduction and pinning or fixation with screws and excision with or without drilling
- Arthroscopic management seems to give as good a result as arthrotomy, with fewer complications
- Compression fractures of the talar dome are rare injuries. They cannot be reduced by closed methods. If open reduction, with or without bone grafting, is elected, prolonged protection from weight bearing is the best means of preventing collapse of the healing area.

1.3.4. Midfoot Fractures

NAVICULAR FRACTURES

Classification (AO/OTA)

- Type A: Extraarticular
- Type B: Partial articular (talon-navicular joint involved)
- Type C: Articular (talo-navicular & naviculo-cuneiform involved)

Management

- Undisplaced / incomplete fractures: short leg cast (non-weight bearing for 4-6weeks)
- Displaced / complete fractures: ORIF (lag screws) and short leg cast (non-weight bearing for 4-6weeks)

CUBOID FRACTURES

Classification (AO/OTA)

- Type A: Extraarticular
- Type B: Partial articular (calcaneo-cuboid or cubo-talsal joints involved)
- Type C: Articular (calcaneo-cuboid and cubo-talsal joints involved)

Management

- Undisplaced / minimal impacted fractures: short leg cast (non-weight bearing for 6weeks)
- Displaced : ORIF (K-wire/lag screws) and short leg cast

1.3.5. Fore-foot Fractures

METATARSAL FRACTURES

Metatarsal Shaft Fractures

- Undisplaced fractures: short leg walking cast.
- Displaced fractures: closed reduction and short leg walking cast
- If significant angulation or intraarticular displacement persists: ORIF

Metatarsal Neck & Head Fractures

- Traction (Chinese finger traps)
- Unstable reductions: percutaneous pinning under fluoroscopic imaging

- If reduction is unacceptable, ORIF with K-wires or plates and screws
- Fracture of the Base of the Fifth Metatarsal

Three distinct patterns occur

- Avulsion fracture
- Jones fracture
- Transverse fracture of the proximal metatarsal diaphysis

Management

- Short leg cast
- In the rare event of a significant displaced intraarticular component, ORIF may be indicated.

1.3.6. Fractures of the Phalanges of the Toes

Management

- A weight-bearing removable immobilization
- Spiral or oblique fracture of the proximal or middle phalanges of the lesser toes can be treated adequately by binding the involved toe to the adjacent uninjured toe (buddy taping)
- Comminuted fractures of the distal phalanx are treated as soft-tissue injuries

1.3.7. Fracture of the Sesamoids of the Great Toe

Management

- Undisplaced fractures: Hard-soled shoe or metatarsal bar
- Displaced fractures: Immobilization in a walking boot or cast, with the toe strapped in flexion
- If conservative modalities have been exhausted: The last resort treatment is excision
- Treatment of fractures in children: The treatment of the majority of fractures in children and adolescents will be conservative. Indications for surgical treatment of fractures in children include:
 - Open fractures
 - Polytrauma
 - Patients with head injuries
 - Femoral fractures in adolescents
 - Femoral neck fractures
 - Certain types of forearm fractures
 - Certain types of physeal injuries
 - Fractures associated with burns

1.4. Fractures in children

1.4.1. Epiphyseal Fracture

The cartilage physeal plates are a region of low strength relative to the surrounding bone and are susceptible to fracture in children.

Classification (Salter-Harris)

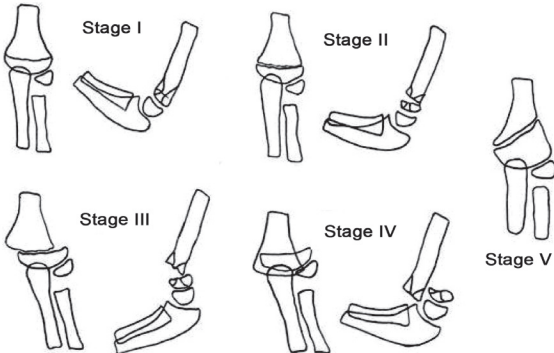
- Type I: Transphyseal fracture involving the hypertrophic and calcified zones
- Type II: Transphyseal fracture that exits the metaphysis
- Type III: Transphyseal fracture that exits the epiphysis
- Type IV: The fracture that traverses the epiphysis and the physis, exiting the metaphysis
- Type V: Crush injuries to the physis

Treatment

- Because physes are near joints and physeal fractures are common, children may suffer injuries to joint surfaces that require careful surgical repair and realignment. Thus, open reduction is more likely in fractures involving physes and joints than in other pediatric fractures.

1.4.2. Supracondylar Fracture of Humerus

RIGAUT AND LAGRANGE PICTURES/IMAGES



Above is a diagram outlining the Lagrange and Rigault classification.

- Stage I: undisplaced fractures, only the anterior cortex is disrupted;

- Stage II: fractures involving both corticals, no or little displacement;
- Stage III: fractures with substantial displacement;
- Stage IV: substantial displacement fractures with no contact between bone fragments;
- Stage V: metaphyseal-diaphyseal fractures.

Classification (Gartland)

- Extension type
 - Type I: Non displaced
 - Type II: Displaced with intact posterior cortex, may be slightly angulated or rotated
 - Type III: Complete displacement, posteromedial or posterolateral
- Flexion type
 - Type I: Non displaced
 - Type II: Displaced with intact anterior cortex
 - Type III: Complete displacement, usually anterolateral

Management (for both Flexion and extension)

- Type I: Immobilization in a long arm cast for 2 to 3 weeks
- Type II: Closed reduction and immobilization
- Type III:
 - Closed reduction and pinning and immobilization
 - ORIF
 - Lateral Condyle Fracture (Jakob):
 - Stage I: Non displaced fractures with intact articular surface
 - Stage II: Complete fracture with moderate displacement
 - Stage III: Complete displacement and rotation with elbow instability

Management

- Stage I: Immobilization for 3 to 4 weeks
- Stage II & III: Closed reduction and immobilization

Note:

If the reduction is unable to be held percutaneous pins / screws may be placed

1.4.3. Radial Neck Fracture

Classification (O'BRIEN) based on degree of angulations

- Type I: 0° - 30°
- Type II: 30° - 60°
- Type III: More than 60°

Management

- Type I: Immobilization for 7 to 10 days followed by early range of motion
- Type II:
 - Manipulative closed reduction and immobilization for 10 to 14 days.
 - Manipulative closed reduction and pinning
- Type III: ORIF

1.4.4. Forearm Fracture

In children, most forearm fractures that involve both bones can be treated successfully by closed reduction and casting. Minor angular mal-alignment can easily be tolerated if rotational alignment of the bone end is accurate. Minimal invasive fixation in case of conservative treatment failure.

METACARPAL & PHALANGEAL FRACTURES

Fractures of the metacarpals and phalanges commonly occur from crush injuries in children (e.g. catching a hand or finger in a door) and are generally quite stable because the periosteum remains intact. Rarely severely angulated or rotationally mal-aligned metacarpals and phalanges can be managed by immobilization for 2–3 weeks.

1.4.5. Pelvic and Lower Limbs Fractures

PELVIC FRACTURE

Pelvic fractures in children are usually seen in conjunction with major blunt trauma. Gross displacement is fairly uncommon and can usually be treated symptomatically because the intact periosteum stabilizes the large flat bones.

HIP FRACTURE

As in the adult, the fracture pattern may disrupt the blood supply of the proximal femoral head and lead to avascular necrosis of the proximal

femoral epiphysis. Femoral neck fractures in children are generally treated by reduction and fixation.

FEMORAL SHAFT FRACTURE

Femoral shaft fractures in children involves the subtrochanteric, shaft and supracondylar region.

Management approach

- Newborn to 2 years: Early spica cast
- From 2 to 10 years of age:
 - Early spica cast
 - Skin traction (> 2 cm overriding)
- From 10-15 years of age:
 - Undisplaced: Conservative treatment
 - Displaced: Operative treatment (flexible nails)

TIBIA SHAFT FRACTURE

Most tibial fractures in children can be adequately aligned and immobilized in above-knee casts. In rare and unstable cases, some open fractures, or fractures in older children may also require operative treatment.

ANKLE FRACTURE AND DISTAL TIBIAL FRACTURE

Ankle fractures and distal tibia fractures in younger children are often either metaphyseal or Salter-Harris type II distal tibial physeal injuries that heal rapidly (Refer to Salter-Harris classification related treatment).

1.5. Open Fractures

Definition: An Open Fracture is when disruption of the skin and underlying soft tissue results in communication between the fracture and the outside environment.

Causes

- Motor vehicle accidents
- Farm accidents
- Sports accidents
- A force large enough to cause a fracture

Signs and symptoms

- Associated with neuro-vascular injury

Diagnosis

- Clinical examination of the specific fracture should include the site of the fracture and severity of the fracture.

Investigations

- FBC
- Blood group and cross match
- PT, PTT, U+E
- Swab from the area
- X-ray of the limb (Lateral and AP views)

Severity assessment (Gustilo-Anderson classification)

- Grade I: The wound is less than 1cm long. It is usually a moderately clean puncture (from inside-out)
- Grade II: The laceration is more than 1 cm long, and there is no extensive soft-tissue damage
- Grade III: These are characterized by extensive damage to soft-tissues, including muscles, skin, and neurovascular structures, and a high degree of contamination

Management

Emergency management

- Emergency ATLS resuscitation
- Monitor level of consciousness (LOC)
- Analgesia preferably an Opioid Analgesic
- Antibiotics
- Remove gross contamination and apply a moist sterile dressing e.g. Betadine dressing
- Splint the limb
- Tetanus Toxoid Prophylaxis
- Urgent surgical debridement, washout and stabilization of the fracture
- Call the orthopaedic specialist after stabilizing the patient and emergency fracture care

Definitive management

- Early administration of systemic antibiotics, timely surgical debridement, skeletal stabilization and delayed wound closure
 - Grade 1: 1st generation cephalosporin
 - Grade 2: 1st generation cephalosporin and/or – an aminoglycoside depending on the level of wound contamination

- Grade 3: 1st generation cephalosporin and an aminoglycoside
- Consent form must be signed before any procedures
- Provide nutritional support to critically ill patients to promote healing process
- Promote patient hygiene to minimize nosocomial infections
- Control of FBC
- Maintain analgesic treatment if required
- Promote psychology support both patient and family members to release anxiety
- Prevent thrombosis by using anti coagulant drugs such as lovenox, etc.
- Treat all contaminated injuries as grade 3 with addition of penicillin and amino glucosides
- Surgical debridement after thorough washing of the wound and irrigation
- Internal fixation versus external fixation
 - Thorough debridement and use of biological fracture fixation techniques
 - Early soft tissue cover
 - Internal fixation with plates or intramedullary nails
 - Follow up is done under the care of the Orthopedic Surgeon
 - Physiotherapy and subsequent surgery
 - Provide rehabilitation
 - Prevention of bed sores for bedridden patients

1.6. Critical Care

1.6.1. Critical Care Severe Traumatic Brain Injury

Definition: A traumatic brain injury (TBI) is defined as a blow or jolt to the head or a penetrating head injury that disrupts the function of the brain. A Concussion, also referred to as a “closed head injury” is a type of TBI.

Assessment of brain injury hinges on evaluation of the Glasgow Coma Score (GCS) and examination of the pupils. Traditionally a GCS of below 9 is considered to reflect severe brain injury.

Classically, TBI has been divided into two distinct periods: primary and secondary brain injury. The primary injury is the result of the

initial, mechanical forces, resulting in shearing and compression of neuronal, glial, and vascular tissue. The secondary injury is described as the consequence of further physiological insults, such as ischaemia, re-perfusion and hypoxia, to areas 'at risk' in the brain in the period after the initial injury.

Causes

- Falls
- Motor vehicle crashes
- Assaults

Signs and symptoms

- Headache with or without traumatic wounds
- Subcutaneous hematoma
- Hemorrhage (Otorrhagia, rhinorrhagia)
- CSF leak (rhinorrhea, otorrhea)
- Seizures
- Pupil dilatation
- Focal deficit (hemiparesis, monoplegia, unilateral mydriasis)
- Lucid interval
- Coma (agitation, confusion or deep coma)
- Skull base fracture (raccoon eyes, battle's sign (after 8-12 h), CSF rhinorrhea/otorrhea, hemotympanum)
- Facial fractures (auscultate the carotids for bruit/possible carotid dissection)

Investigations

- Head CT-Scan
- Cervical spine x-ray or CT-scan
- Chest x-ray
- Abdominal US
- Transcranial Doppler US
- FBC, coagulation tests, Biochemistry
- Arterial Blood Gas (ABG), central venous blood gas (internal jugular Saturation venous O₂)
- Any other investigation for associated injuries

Complications

- Posttraumatic seizures
- Hydrocephalus
- Deep vein thrombosis
- Spasticity
- GI and GU complications

- Gait abnormalities
- Autonomic dysfunction syndrome
- Diabetes insipidus
- Brain herniation and death

Management

Treatment of first choice

- Early detection and minimization of any secondary insults
- Cervical spine stabilization
- Avoid moving the patient if at all possible
- Secure and preserve the airway
- Maintain and support breathing
- Intubation and mechanical ventilation
- Maintain effective circulation with IV fluids with isotonic solutions
- Maintenance of adequate mean BP in order to sustain an adequate cerebral perfusion pressure (CPP) ; $CPP = MAP - ICP$ (targeted CPP:70-110mmhg)
- Effective pain relief
- Arrest bleeding
- Regular evaluation of GCS and pupillary asymmetry and reaction to light
- Ensure Normoxemia, normoglycemia, normo or mild hypothermia, normonatremia and normocapnia (35-38mmhg)
- Head straight and elevated at 300C
- Prevention of seizures with Phenytoin 5mg/kg/24hrs or Phenobarbital 5mg/kg/24hrs Slow IV

Surgical Treatment

- Surgical decompression or craniectomy are indicated in:
 - Open, depressed skull fracture
 - Subdural or epidural hematomas
 - Intraparenchymal hemorrhages or contusions resulting in significant mass effect or midline shift. Pre-operation considerations include associated injuries like intra-abdominal, orthopedic, spinal cord and other organ trauma
- Ventilation & oxygenation may be inadequate
- CHOICE OF ANESTHESIA (GA)
 - Rapid sequence Induction (RSI): *Lidocaine IV* (1.5 mg/kg) and/or *Fentanyl* (1-4 mcg/kg) IV, *Barbiturates*

(*thiopental* 3-5mg/kg) or *Etomidate* 0.3 mg/kg, maintenance with *Isoflurane* or *Sevoflurane*, muscle relaxants: *Vecuronium* 0.1 mg/kg or *Pancuronium* 0.1 mg/kg or *Tracurium* 0.5 mg/kg

- INTRAOPERATIVE MONITORING
 - Monitors/Line Placement, standard monitors plus intra-arterial BP monitor, ideally placed prior to induction, CVP monitoring, ICP monitor may be placed by neurosurgeons, Maintain CPP above 70mmHg, avoid increasing ICP, maintain mild hypothermia, avoid hypoxemia & hypercarbia, treat anemia, coagulopathy, volume resuscitate with isotonic, glucose-free solutions or colloids and, blood or blood products if indicated, avoid hyperglycemia (keep glucose <150 mg/dL) and hypoglycemia.
- MANAGEMENT OF ELEVATED ICP
 - Hyperventilate to PaCO₂ of 25-30 mmHg, Increase depth of anesthesia with thiopental; avoid high levels of volatile osmotic diuresis with mannitol 0.25-1 gm/kg IV bolus over 10-20 min or loop diuretics (furosemide), drain CSF through ventricular drainage catheter placed by neurosurgeons, maintain temperature at 33-35° C.
- MANAGEMENT OF HYPOTENSION
 - Use vasopressors (norepinephrine 0.01-0.1 µg/kg/min post-operative period, manage pain, sedation with midazolam 5-15 mg/hour + Fentanyl 50-150 µg/hour may be required if patient is left intubated.

1.6.2. Critical care of multiple injuries

Definition: Multi-trauma are physical insults or injuries occurring simultaneously on several parts of the body.

Causes

- Mechanical or kinetic energy- blunt or penetrating injury
- Thermal energy- injury due to heat or cold
- Chemical energy- acid or alkaline exposure
- Radiant energy- exposure to radiation
- Electrical energy- electrocution
- Oxygen deprivation- smoke inhalation or drowning

Signs and symptoms

- Pain and swelling
- Deformity
- Lesions with bleeding
- Altered mental status or unconsciousness
- Hypotension or shock

Life threatening features include: chest tension pneumothorax, flail chest, pericardial tamponade, myocardial contusion, open chest wound, hemothorax, intra-abdominal bleeding, pelvis / femur fracture, spine fracture / cord injury, head injury (see Severe Head Injury), extremity fracture / dislocation, HEENT (airway obstruction).

Investigations

- X-rays of the chest, pelvic and C-spine
- Abdominal US
- Head CT-Scan if head Injury
- Body scan
- X-ray of affected limbs
- FBC, Blood group and cross-match, coagulation tests
- Chemistry (electrolytes, transaminases, CPK, Troponin)

Complications

- Haemorrhage infection/ Sepsis
- Multi organ failure
- Deep venous thrombosis
- Fat air embolism

Management

Treatment of first choice

- Adult Assessment Procedure focusing on initial C-spine, ABCD and level of responsiveness (see ATLS)
- Spinal immobilization
- Airway protection and/or maintenance if appropriate
- Assess Vital Signs and GCS

If hypotension

- Give IV fluids: Normal saline until you get a mean arterial pressure > 60 mmHg Splint Suspected fractures consider pelvic binding/ radiological embolization if available
- Control external hemorrhage
- Tension Pneumothorax: chest decompression
- Laparotomy if abdominal injuries

- Head injury protocol (if head injury)
- Blood and/or blood components transfusion if needed

Supportive treatment

- Dialysis in case of renal failure
- Mechanical ventilation in case of ALI/ARDS
- Inotropic drugs like dobutamine 5-20 µg/kg/min in case of cardiogenic shock due to myocardial contusion
- NGT for enteral feeding
- Prevention of DVT with LMWH e.g. Enoxaparine 40mg SC/day (starting from day 5 if no contraindications)

1.7. Dislocations

1.7.1. General Consideration

Definition: Complete separation and loss of 2 articulating bone contact surfaces. A partial or incomplete dislocation is known as a subluxation.

Causes

- Direct Trauma
 - High Energy trauma
 - Road traffic accident
 - Fall from Heights
 - Sports injuries
 - Industrial injuries
 - Low Energy Trauma
 - Sports injuries
- Indirect Trauma
 - Varus, Valgus and rotational stress

Signs and symptoms

- Pain
- Tenderness
- Deformity
- Swelling
- Decreased range of motion
- Shortening
- Effusion

Investigations

- X-Rays (Lateral view, Anteroposterior View)
- CT Scan
- MRI

1.7.2. Acromio-Clavicular Joint Dislocation

Definition: Classified in 6 different types depending on which ligaments are sprained or torn.

- Type 1- Sprain of the acromioclavicular ligament
 - Joint tenderness
 - Minimal pain with arm motion
 - No pain in Coraco-Clavicular Interspace
- Type 2- Torn Acromioclavicular Ligament with sprain Coraco-Clavicular Ligament
 - Joint tenderness in both acromioclavicular and coracoclavicular interspace
 - Distal clavicle is slightly superior to Acromion and mobile to palpation
- Type 3 – Torn both Acromio clavicular and Coraco-Clavicular ligament
 - Acromio clavicular Joint tenderness and coraco clavicular widening is evident
- Type 4 – Type 3 and posterior displacement of the distal Clavicle into or through the Trapezius
 - More pain exists than in type 3 and distal clavicle is displaced posteriorly away from the clavicle.
- Type 5- Type 3 and grossly and severely displaced distal Clavicle superiorly (radiography demonstrates the Coraco-clavicular inter-space to be 100% to 300% greater than normal)
 - Symptoms as in type 3 but this type is typically associated with tenting of the skin
- Type 6 – Dislocated Acromio Clavicular Joint with Clavicle displaced inferiorly. (shoulder has Flat appearance with a prominent Acromion)
 - Shoulder has flat appearance with a prominent Acromion

Note:

Associated clavicle, upper rib fractures and brachial plexus injuries are due to high energy trauma in this type

Investigations

- Antero-Posterior x-ray for both shoulders (comparison)
- Stress x-ray of the affected shoulder (holding weight) in case of doubt

Complications

- Associated fractures (Clavicle, Acromion and Coracoids process)
- Post Traumatic osteoarthritis
- Type 6 could be associated with a pneumothorax

Management

- Type 1: Rest 7-10 Days with an Arm sling (refrain from full activity for 2 weeks)
- Type 2: Use of Arm sling for 1-2 weeks (refrain from heavy activity for 6 weeks)
- Type 3: Conservative Treatment (arm sling) or Surgical Treatment (surgical repair)
- Type 4, Type 5 and Type 6: Open reduction and surgical Repair of the Coraco-Clavicular Ligament

1.7.3. Shoulder Dislocations**Description**

- Most common dislocated joint of the body
- Most shoulder dislocations are anterior
- Posterior dislocations are less frequent and difficult to diagnose
- Inferior and superior dislocations are very rare

Signs and Symptoms**ANTERIOR DISLOCATIONS**

- Pain, tenderness and swelling of the affected shoulder
- Arm of the affected shoulder is held in abduction and External Rotation
- Decreased Range of motion
- Loss of deltoid contour compared with contralateral side
- Prominence of the Acromion and palpable head of the humerus anteriorly in the Axilla

Note:

Careful assessment of the neurovascular status. (Evaluate sensory and motor function of the musculocutaneous and radial nerves. Compare distal pulses on both extremities.)

Investigations

- Antero posterior and lateral x-rays
- CT Scan and MRI (to assess the rotator cuff)

Complications

- Recurrent dislocation
- Soft tissue injuries (rotator cuff injury)
- Vascular Injury- Axillary Artery (*Rare: only in elderly patients with atherosclerosis*)
- Nerve injury especially the Musculocutaneous and Axillary Nerve
- Osseous lesions
- Post traumatic osteoarthritis

Management

Conservative (closed reduction)

- Analgesics and/or Sedation
- Always conservative for acute anterior shoulder dislocations
- Arm sling after closed reduction for 2-3 weeks (elderly patients) and 6 weeks for (young patients)

Surgical

- Indication: Chronic dislocation, soft tissue interposition, fracture dislocation

POSTERIOR DISLOCATION

Signs and symptoms

- Arm of the affected shoulder is held in adduction and internal rotation
- Pain, tenderness and swelling of the affected shoulder
- Decreased range of motion
- Most commonly missed injury (60-70% are missed)

Investigations

- Antero posterior and lateral x-rays
- CT Scan (to assess the associated fractures: humeral head)

Complications

- Recurrent dislocation
- Nerve Injury especially the Axillary nerve

- Osseous lesions
- Post traumatic osteoarthritis

Management

Conservative (Closed reduction)

- Analgesics and/or sedation
- Always conservative for acute posterior shoulder dislocations
- Arm sling after closed reduction for 2-3 weeks (elderly patients) and 6 weeks for (young patients)

Surgical

- Indication: Chronic dislocation, soft tissue interposition, fracture dislocation

Recommendations

- Physical therapy under supervision post immobilization removal
- Pre and post reduction: x-Ray and neuro-vascular status evaluation is mandatory

1.7.4. Elbow Dislocation

Description

- Posterior dislocations account for most elbow dislocations
- Most common in young population

Classification

- Posterior 90% of elbow dislocations
- Anterior
- Lateral
- Medial
- Divergent

POSTERIOR DISLOCATIONS

Signs and Symptoms

- Pain - intense, focused around the elbow joint
- Extremely limited range of motion
- Massive ante-cubital swelling (be aware of compartment syndrome)
- Elbow is flexed, with an exaggerated prominence of the olecranon

Investigations

- X-ray antero- posterior and lateral views

Complications

- Compartment syndrome (Vascular or Neuro: compromise)
- loss of motion (stiffness) due to long term immobilization
- Instability/ re-dislocation
- Heterotopic ossification

Management

Conservative (Closed reduction):

- Analgesics and/or sedation
- Always conservative for acute posterior elbow dislocations
- Above elbow posterior splint for 3 weeks (young patient) and up to 10 days (for elderly)

Surgical

- Indication: Chronic dislocation, soft tissue and/or bony entrapment, fracture dislocation, recurrent instability.

Recommendations

- Physical therapy under supervision post immobilization removal
- Pre and post reduction: X-Ray and Neuro-Vascular status evaluation is mandatory

1.7.5. Hip Dislocation

Description

- Traumatic hip dislocation of the hip joint may occur with or without fracture of the acetabulum of the proximal end of the femur. Hip dislocations are classified based on the relationship of the femur head to the Acetabulum and on whether associated fractures are present

Causes of hip dislocations

- High energy traffic accidents
- Fall from heights
- Industrial injuries

Investigation

- X-ray Antero posterior of the pelvis
- Oblique radiographic projections (Judet views)
- CT Scan (Preferably post reduction)

POSTERIOR HIP DISLOCATION

Classification

- Posterior dislocation is the most common and accounts for 90% of all hip dislocations.
- Classification of Posterior dislocations (Thompson and Epstein Classification)
 - Type 1- Simple dislocation with or without any significant posterior wall fragment
 - Type 2- Dislocation associated with a single large posterior wall fragment
 - Type 3- Dislocation with a comminuted posterior wall fragment
 - Type 4- Dislocation with fracture of the acetabular floor
 - Type 5 – Dislocation with fracture of the femoral head

Signs and Symptoms

- Severe pain
- Shortening, adduction flexion and internal rotation of the affected limb
- Decreased motion of the lower extremity on the affected side

Note:

Full trauma survey is critical due to the high energy nature of the injury.

ANTERIOR HIP DISLOCATION

Classification

Anterior dislocations are not very common

- Type I: superior dislocation including pubic and subspinous
- Type II: inferior dislocation including obturator and perineal

Signs and symptoms

- Severe pain
- Abduction flexion and external rotation of the affected limb
- Decreased motion of the lower extremity on the affected side

Complications of hip dislocations

- Neurovascular injury
- Thromboembolism
- Avascular osteonecrosis
- Post traumatic osteoarthritis
- Recurrent dislocations
- Heterotopic ossifications

Management of hip dislocations

Reduction should be expedient to decrease the risk of osteonecrosis of the femoral head.

Conservative treatment

- Closed reduction under anesthesia
- Skin or skeletal traction (2-3 weeks)

Open reduction

- Indications for open reduction
 - Failure of closed reduction
 - Non concentric reduction
 - Fracture of the acetabulum or femur head that requires either excision or ORIF
 - Ipsilateral femoral neck fracture

1.7.6. Traumatic Knee Dislocation

Definition: Is the complete displacement of the tibia with respect to the femur and with disruption of 3 or more of the stabilizing ligaments.

- Extremely rare but may be limb threatening (associated with vascular injuries - Popliteal Artery)
- Should be treated as an orthopedic emergency

Causes

- Motor vehicle accidents
- Falls from heights
- Industrial-related accidents
- Sports-related injuries

Signs and Symptoms

- Severe pain
- Extreme swelling and gross knee derformity with or without neurovascular compromise

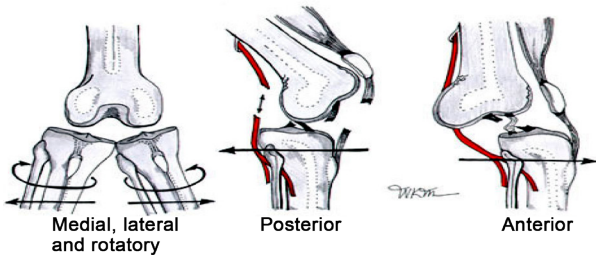
Investigations

- Anteroposterior and lateral x-rays
- MRI

Complications

- Neurovascular
- Ligamentous instability
- Stiffness (due to prolonged immobilization and extend of soft tissue injury)

Classification



- Anterior: Dislocation is often caused by severe knee hyperextension
- Posterior: Dislocation occurs with anterior-to-posterior force to the proximal tibia, such as a dashboard type of injury or a high-energy fall on a flexed knee
- Lateral: Valgus force with disrupted medial supporting structures and often with tear of both cruciate ligaments
- Medial: Varus Force with disruption of lateral and post lateral structures
- Rotational: Varus and Valgus with rotatory component.

Management

A knee dislocation is a potentially limb threatening condition, therefore immediate reduction is recommended even before a radiography evaluation.

Conservative

- Immediate closed reduction and immobilization at 20-30° of flexion for 6 weeks
- Range of motion/exercise should be instituted after adequate soft tissue healing 6-12 weeks

Surgical

- Indications
 - Unsuccessful closed reduction
 - Open injuries
 - Vascular injuries
 - Residual soft tissue interposition

Recommendations

- Acute repair of lateral ligament followed by early functional bracing is advised (meniscal injuries to be addressed at time of surgery)
- Medial collateral injuries generally heal without surgery
- The role of cruciate reconstruction in the acute setting remains controversial

1.7.7. Patellar Dislocation

Description: Patella dislocation is more common particularly in females due to physiologic laxity and in patients with hyper mobility (athletes)

Causes

- Physiological laxity
- Direct trauma to the patella
- Connective tissue disease (Marfan Syndrome)
- Congenital abnormality of the patella and trochlea
- Hypoplasia of the Vastus Medialis muscle
- Hypertrophy of the lateral retinacular

Signs and symptoms

- Pain focused around the knee joint
- Inability to flex knee
- Hemarthrosis
- Swelling with tenderness of the knee
- Palpated displaced patella

Investigation

- X-ray of the knee (Anteroposterior and Axial views)

Complications

- Recurrent dislocation
- Re-dislocation
- Patella-femoral Arthritis

Management

Conservative

- Closed reduction with cylinder casting for 2- 3 weeks
- Isometric quadriceps exercises after removal of the cast

Surgery

- Recurrent episodes require operative repair

1.8. Surgical Infections

1.8.1. Septic Arthritis

Definition: Septic arthritis is the inflammation of a synovial membrane with purulent effusion into the joint space usually caused by bacteria. It is a surgical emergency. Typically it affects mono-articular joints. Commonly affecting the knees, hips and shoulders.

Pathophysiology

- Bacteria can gain entrances to a joint via three routes:
 - Hematogenous spread
 - Direct inoculation
 - Direct extension from an adjacent focus of infection
- Hematogenous infection is the most common type and usually affects people who have an underlying medical illness
- Predisposing factors include
 - Immune deficiencies
 - Chronic disease
 - Intravenous drug abuse
 - Local joint trauma
 - Recent sexual contact (gonococcus sepsis)

Causes

- Staphylococcus Aureus
- Streptococcus
- Gram negative bacteria

Signs and symptoms

- Warm, painful and swollen joint
- Erythema and tenderness
- Limitation of motion
- Pyrexia
- Antalgic posture of the limb

Investigations

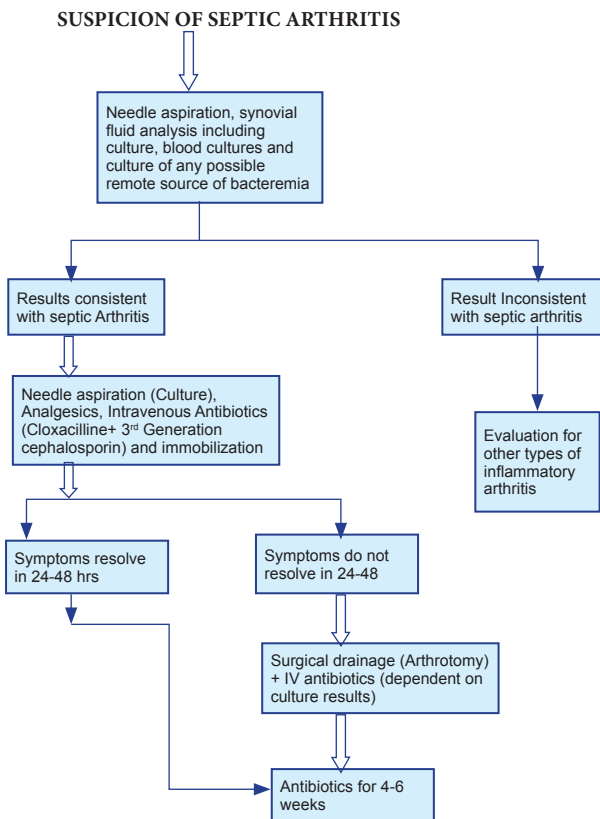
- FBC: Often leucocytosis with a left shift
- ESR and CRP
- Blood cultures: 50% positive in S.aureus infection, very poor for N. gonorrhoea

- urethral, cervical, pharyngeal and rectal swabs
- Synovial fluid analysis: gram stain, culture, cell counts, crystal analysis
- X-ray of the joint
 - Often normal initially
 - Soft tissue swelling around the joint, widening of the joint space, displacement of tissue planes
 - Bony erosions and joint space narrowing, sclerosis, and patchy demineralization all in later stages
- Ultrasound of the joint

Complications

- Septicemia
- Dislocations
- Growth plate damage in children
- Osteomyelitis
- Degenerative arthritis
- Avascularis necrosis in hip and shoulder

Management



1.8.2. Acute Osteomyelitis

Definition: Osteomyelitis is a bone infection

Cause/Etiology

- Bacterial

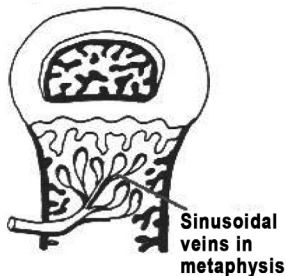
Pathogenesis

- Inflammation
 - Acute inflammatory reaction with vascular bacterial congestion
 - Rise in intra-osseous pressure causing intense pain
- Suppuration
 - At 2-3 days pus forms within the bone and forces its way down the haversian canals to the surface where it forms a sub-periosteal abscess
 - The pus can spread from here back into the bone, into an adjacent joint or into the soft tissues (where there is an intra-articular physis)
 - Vertebral infection can spread through the end plate, disc and into the next vertebral body
- Necrosis
 - At 7 days, rising pressure, vascular stasis, infective thrombosis and periosteal stripping compromise the blood supply to the bone resulting in bone death resulting in a sequestrum
 - New bone formation
 - At 10-14 days this forms from the deep surface of the stripped periosteum forming the involucrum
- Resolution
 - With release of the pressure and appropriate antibiotics healing can occur
 - There may be permanent deformity
 - Unpublished work (quoted in Dee) shows that experimentally bacteria injected intravenously will settle in the metaphyses of bone preferentially

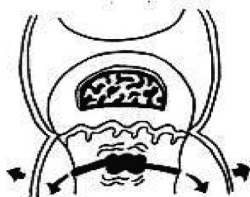
Note:

- In 10% of cases there is more than one site of infection

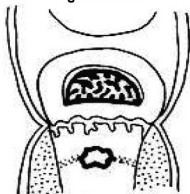
1. Spread to Metaphysis



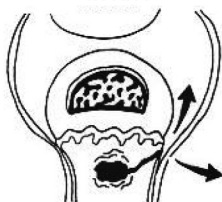
2. Lifts periosteum



3. Involucrum formed around sequestrum



4. Local spread to joint & soft tissues



Signs and Symptoms

- Children (invariably)
 - Pain, malaise, fever
 - Limp or not weight bearing
- Infants
 - Failure to thrive, drowsiness, irritable
- Adults
 - The most common site is long bones
 - Local erythema, swelling and tenderness indicates that the pus has broken through the periosteum

Investigations

- FBC: Often leucocytosis with a left shift
- ESR and CRP
- Blood cultures

- X-ray of the joint
 - Often normal initially
 - Soft tissue swelling around the joint, widening of the joint space, displacement of tissue planes
 - Bony erosions and joint space narrowing, sclerosis, and patchy demineralization all in later stages
- Ultrasonography

Complications

- Recurrent bone infection
- Pathologic fractures
- Bone destruction
- Chronic osteomyelitis
- Impaired bone growth

Management

Non Operative

- ANTIBIOTIC ADMINISTRATION:
 - It is recommended to start empiric treatment with a regimen that caters for S.aureus as the culture results are awaited
 - Empiric regimen
 - IV CLOXACILLIN and A 3RD GENERATION CEPALOSPORIN (e.g. ceftriazone)
- OR**
- IV OXACILLIN can be used in the place of cloxacillin with the 3rd generation cephalosporin
 - Culture results to guide definitive antibiotherapy
 - The change to oral medication will depend on the clinical response i.e. fevers ceasing and decreasing CRP and ESR, with the generally accepted course being of 1week IV treatment then a change to oral medication
 - The recommended minimal duration of drug therapy is 6 weeks

Operative

- Periosteal abscess should be managed surgically.

1.8.3. Chronic Osteomyelitis

Definition: Exogenous or hematogenous infection that has gone untreated or has failed to respond to treatment.

Signs and symptoms

- Pain
- Swelling/oedema
- Often draining sinus
- Sometimes deformity

Investigations

- FBC
- ESR and CRP
- Blood cultures
- Tissue culture and sensitivity
- X-ray (Anteroposterior and lateral views)
- CT Scan
- MRI
- Scintigraphy

Complications

- Recurrent bone infection
- Pathologic fractures
- Bone destruction
- Impaired bone growth
- Skin neoplasm

Management

- Surgical debridement (Sequestrectomy and curettage)
- Systemic and local antibiotics guided by the results of the antibiogram
- Analgesics and immobilization
- Dead space management (irrigation, muscle flap, beads or spacers)
- Amputation
 - Indication: Association of any of the following
 - Septicemia
 - Extreme deformities and Extensive Infection
 - Severely compromised soft tissue

1.9. Hand Surgery

1.9.1. Fracture of Wrist Bones

Description

- Carpal/wrist bones are in 2 rows:
 - A *wrist fracture* is a break in one or more of the bones in the *wrist*.
 - The proximal row which is made from radial to ulna sides of the scaphoid, lunate, triquetrum and pisiform bones.
 - The distal row which is made from radial to ulna of the trapezium, trapezoid, capitate and hamate bones.

Causes

- Fall on the outstretched hand and extended wrist
- Motor vehicle accident
- Sports contact injury

1.9.2. Fracture of the Scaphoid Bone

Description: Scaphoid fractures are by far the most common of the carpal fractures, estimated at 70-79%.

Classification

Herbert classification of scaphoid fractures

- Type A fractures are stable and acute including:
 - A1: Fracture of the tubercle
 - A2: Incomplete fractures of the scaphoid waist
- Type B fractures are unstable and include:
 - B1: Distal oblique fractures
 - B2: Complete fracture of the waist
 - B3: Proximal pole fractures
 - B4: Transscaphoid perilunate fracture dislocation of the carpus
- Type C fractures are characterized by delayed union.
- Type D fractures are characterized by established non-union
 - D1: Fibrous union
 - D2: Pseudarthrosis

Signs and Symptoms

- Pain and swelling of the radial wrist
- Swelling and pain on palpation of the anatomic snuff box
- Limited range of motion of the wrist
- Radial deviation and flexion of the wrist elicit pain
- Axial load to the first metacarpal elicit pain
- Diminished grip compared to the other hand

Investigations

- Plain x-ray: (Poste-Anterior, true lateral and semi-pronate oblique)
- CT Scan and MRI: Only for suspected fractures that can't be found on plain x-ray

Complications

- Bone Necrosis
- Pseudo Arthrosis

Management

Conservative treatment

- Short arm casting for 12 weeks
- Physiotherapy after removal of casting

Surgical

- Open reduction and internal fixation (ORIF) ± bone grafting associated with short arm casting for 8 weeks
- Physiotherapy after removal of casting

Recommendations

- If patients still feel pain after conservative treatment refer to Hand or Orthopedic surgery.
- If plain x-ray seems normal despite clinical suspicion of fracture, repeat x-ray after one week.
- Refer all unsure cases to a Hand or Orthopedic surgeon.

1.9.3. Perilunate Dislocation and Perilunate Fracture Dislocation

Definition: Perilunate dislocation and Perilunate fracture dislocation are injuries that involve traumatic rupture of the Radio-Scaphal Capitate (RSC) ligament, the scapholunate interosseous and lunotriquetral interosseous ligament.

Signs and symptoms

- Pain and marked swelling of the wrist
- Wrist is dislocated dorsally and radius is prominent volarly
- Paresthesia in the median nerve territory
- For lunate dislocation the lunate alone is prominent volarly

Investigations

- Plain x-ray: (Poste-Anterior, true lateral and semi-pronate oblique)
- CT Scan and MRI

Complications

- Median nerve palsy
- Post traumatic arthrosis
- Open fracture

Management

- Closed reduction and casting for 8 weeks if reduction is stable
- Unstable Reduction: Closed reduction and percutaneous pin fixation
- Severe Ligament injuries: Open reduction, Ligament Repair and Fixation.
- Physiotherapy after removal of casting

Recommendation

- CT scan and/or MRI should be prescribed by the surgeon who is going to operate.

1.9.4. Other Wrist Bone Fractures

Description: Commonly associated with above carpal bone fractures.

Signs and symptoms

- Decreased range of motion of the wrist
- Most pain can be radial or ulna depending on the bone involved
- Pain and swelling of the wrist
- Decreased hand grip

Investigations

- Plain x-ray: (Poste-Anterior, true lateral and semi-pronate oblique)
- CT Scan and MRI

Management

Conservative: Short arm casting for 8 weeks

Surgical: ORIF with short arm casting.

Physiotherapy after removal of casting

1.9.5. Metacarpal Fractures

Description: Metacarpal bones are located between carpal bones and phalanges. From radial to ulna we have thumb (First) Metacarpal and second to fifth metacarpal.

- Fractures will be described according to:
 - Whether closed or open
 - Finger involved
 - Site (base, shaft, neck and head)
 - Type of Fracture (horizontal, oblique, spiral and comminuted)
 - Joint involvement

Causes

- Falls
- Blunt injuries
- Penetrating injuries
- Sport contact injuries

Signs and Symptoms

- Pain
- Swelling of the hand, hematoma and bruising overlying skin
- Decreased range of motion of the fingers
- Shortening of fingers involved
- Rotation of finger
- Angulation

Investigation

- Plain x-ray (Antero-posterior and oblique views)

Management

Conservative

- Closed reduction and volar splinting in functional position for 6 weeks
- Physiotherapy after removing the splint

Surgical

- Closed reduction and percutaneous pin fixation
- Open reduction and internal fixation

Recommendations

- Keep the hand elevated to decrease pain and swelling
- Make sure the finger is not rotated after fixation

1.9.6. Bennett's and Rolando's Fractures

Description

- Bennett's fracture is an intra articular fracture of the base of the thumb metacarpal characterized by one small ulna fragment.
- Rolando's fracture is a comminuted intra articular fracture of the base of the thumb metacarpal.

Causes

- Fall with axial loading through the thumb metacarpal
- Direct blow of the thumb metacarpal
- Injury involving forced abduction of the thumb

Signs and symptoms

- Pain and swelling
- Decreased range of motion of the thumb
- Shortening of the thumb
- Dorsal and radial displacement of the metacarpal bone

Investigations

- Plain x-ray (Antero-posterial and oblique views)

Management

Surgical

- If the Bennett's fragment is less than 15-20% of the articular surface: Closed reduction and percutaneous pin fixation followed by a thumb spica splint for 4-6 weeks.
- Open reduction and internal fixation. (If the Bennett's fragment is greater than 20% or articular step off after pin fixation is greater than 1 mm)
- For Rolando's fracture: Always do Open reduction and internal fixation (ORIF)

Recommendations

- Always refer Bennett's or Rolando's fractures to the orthopedic surgeons after immobilization in a splint.

1.9.7. Boxer's Fracture

Description: Fracture of the neck of the fifth metacarpal.

Causes

- Direct blow
- After punching a person or object such as a wall

Signs and symptoms

- Pain and swelling at the base of small finger
- Decreased range of motion
- Deformity over the dorsal aspect of the metacarpal
- Loss of the knuckle definition
- Volar displacement of the head of the metacarpal

Investigation

- Plain x-ray (Antero-posterial and oblique views)

Management

- If angulation is less than 40%: Closed reduction and splint
- If angulation is more than 40% : Closed reduction and percutaneous pin fixation or open reduction and ORIF (Open reduction and Internal Fixation)

Recommendation

- Check for rotation deformity after fixation

1.9.8. Fractures of Phalanges

Proximal and middle phalanges

Definition/Description: Fracture of the bones of the proximal or middle phalanges of the fingers. Fracture can be extra-articular or intra-articular

Causes

- Falls
- Direct blows
- Sport contact injuries
- Machinery injuries

Signs and symptoms

- Pain and swelling of the fingers involved
- Decreased range of motion
- Ecchymosis
- Rotation deformity
- Angulation
- Shortening of the fingers

Investigation

- Plain x-ray (AP, lateral and oblique views)

Complication

- Digital neuro-vascular bundle injuries

Management

Conservative (Extra-articular fractures)

- Closed reduction,
 - if stable do buddy strapping for 4 weeks
 - If reduction not stable then do surgery
- Surgical (Unstable Fractures and/or Intra-articular fractures)

- Closed reduction with per-cutaneous pin fixation

Or

- Open reduction and internal fixation with plates and screws

Recommendation

- Always check sensation and perfusion of the fingers before and after treatment

1.9.9. Distal Phalanges and Nail Bed Injuries

Description: Distal phalanges fractures are often associated with nail bed laceration.

Causes

- Crush injuries (from doors mostly in children)
- Work related trauma
- Falls

Signs and symptoms

- Pain and swelling of the fingertip
- Lacerations and/or hematoma of the nail bed
- Deformity of the fingertip

Investigation

- Plain x-ray (AP and lateral views)

Complication

- Traumatic amputation of the fingertip

Management

- If fracture is associated with nail bed laceration, repairing the laceration will reduce the fracture. Then stabilize with a Zimmer splint for 4 weeks.
- Otherwise do fixation with an axial per-cutaneous pin if the distal fragment is big enough.

1.9.10. Dislocations of the Hand Joints

Definition: A dislocation is a misalignment of the bones forming a joint. Metacarpophalangeal joints and interphalangeal are the most commonly involved.

Causes

- Falls
- Sport injuries

Signs and symptoms

- Pain and swelling of the joint involved
- Decreased range of motion
- Ecchymosis
- Joint deformity

Investigation

- Plain x-ray (AP, lateral and/or oblique views)

Complication

- Nerve injuries

Management

Conservative

- Relocate under nerve block or general anesthesia. If relocation is difficult under those circumstances do an open reduction
- Splinting in functional position for 4 weeks and then physiotherapy

Surgical

- Sometime the volar plate or tendons can be entrapped into the joint and that is why it may be impossible to do a closed reduction.

Recommendation

- Refer to orthopedic surgeon or hand surgeon any dislocation that can't be relocated conservatively.

1.9.11. Burns

Wound management of the burned hand follows the general principles of burn wound management. But there are a few things that are specific to the hands. For the general principle please refer to the burns chapter.

- Specifics to hands in acute burn management
 - Every burned hand must be splinted in a functional position
 - Every finger must be dressed separately to avoid synechia
 - Daily mobilization of fingers
 - Early skin grafting when required (do not use skin staples in hands)
- Specifics to hands in post burn reconstruction
 - When releasing scar contractures, do not use split thickness skin grafts. Cover defects with full thickness skin grafts or flaps.
 - Release scar contractures in stages from proximal to distal.

1.9.12. Infections

PARONYCHIA ABCESS

Definition: It is the infection of the soft tissue fold around the nail. It is the most common infection of the hand.

Causes

- Splinters
- Manicure instruments
- Nail biting

Signs and symptoms

- Erythema, swelling, and tenderness immediately adjacent to the nail
- If left untreated the abscess may extend below the nail bed and track into the pulp

Investigations

- Plain x-ray to exclude bone involvement in late or advanced presentations
- Microbiology culture and sensitivity of pus and/or necrotic tissue

Complications

- Pulp abscess
- Bone involvement
- Extensive soft tissue necrosis

Management

Conservative

- For early presentations: warm soaks and systemic antibiotics

Surgical

- Abscess drainage
- Debridement of necrotic tissues
- Systemic antibiotics for 6 weeks if the bone is involved

PULP ABSCESS (FELON)

Definition: It is a subcutaneous abscess of the volar aspect of the fingertip

Causes

- Splinters
- Thorns

Signs and symptoms

- Severe throbbing pain
- Tension
- Swelling of the entire pulp but does not extend proximal to the distal interphalangeal crease

Investigations

- Plain x-ray to exclude bone involvement
- Microbiology culture and sensitivity of pus and/or necrotic tissue

Complications

- Bone involvement
- Extensive soft tissue necrosis

Management

- Lateral incision and drainage
- Systemic antibiotics

TENOSYNOVITIS

Definition: It is the infection of the flexor tendon sheath.

Causes

- Wound bite
- Any other penetrating injury

Signs and symptoms

- Semi flexed position of the finger
- Fusiform swelling (Sausage type)
- Excessive tenderness limited to the course of the flexor tendon sheath
- Excessive pain on passive extension

Investigations

- Plain x-ray to exclude bone involvement
- Microbiology culture and sensitivity of pus and/or necrotic tissue

Complications

- Proximal extension of the infection to the hand and forearm
- Extensive soft tissue destruction
- Bone involvement

Management

- Incision and drainage of the tendon sheath (refer to text books for description of proper technique)
- Systemic antibiotics

HUMAN BITES (PUNCH BITES)

Definition: It is the infection of the metacarpal phalangeal joint as a result of an injury by tooth.

Cause

- Human bites

Signs and symptoms

- Excessive tenderness and swelling over the involved knuckle
- Decreased range of motion
- Pus discharge from the wound

Investigations

- Plain x-ray
- Microbiology culture and sensitivity of pus and/or necrotic tissue

Complications

- Complete destruction of the joint
- Extensive soft tissue destruction

Management

- Opening of the joint and adequate debridement (as many as required)
- Systemic antibiotics

DEEP SPACE INFECTIONS OF THE HAND

Description: The hand has three anatomically defined potential spaces and one forearm potential space. These spaces are the thenar, midpalmar and hypothenar spaces in the hand and Parona's space in the forearm. A deep seated infection can involve those spaces.

Causes

- Penetrating injuries
- Retained foreign bodies

Signs and Symptoms

- Excessive pain
- Tension and swelling of the hand
- Decreased range of motion

Investigations

- FBC
- MCS (Microbiology culture and sensitivity) of pus and/or necrotic tissue
- US
- X-ray

Complications

- Extension of the infection into the forearm
- Extensive soft tissue destruction
- Frozen hand

Management

- Adequate incision and drainage plus debridement of necrotic tissue
- Systemic antibiotics
- Splinting
- Early mobilization

1.9.13. Tendon Injuries

Definition: A tendon is a fibrous structure that connects a muscle to a bone. A tendon injury is the laceration of a tendon.

Causes

- Penetrating injuries
- Traumatic forced extensions
- Pathologic ruptures
- (Note): Flexor and Extensor tendon injuries will be discussed separately

Types

FLEXOR TENDON INJURIES ■ Laceration or rupture of tendons that flex the wrists and fingers

EXTENSOR TENDON INJURIES: Laceration or rupture of tendons that extend the wrists and fingers

Signs and symptoms

General

- Pain
- Swelling
- Tenderness
- Look for loss of sensation to exclude associated nerve injury
- Check for perfusion to exclude associated arterial injuries

Specific in flexor Tendor Injuries

- Loss of active flexion of the wrist or fingers
- The finger involved is in extension compared to the other fingers
- Presence of laceration on the volar aspect of the forearm, wrist, hand or fingers

Specific in Extensor Tendon Injuries

- Loss of active extension of the wrist or fingers
- Presence of laceration on the dorsal aspect of the forearm, wrist, hand or fingers

Investigations

- Plain x-ray to exclude associated fractures
- FBC

Management

- Before transferring the patient to a hand or orthopaedic surgeon do the following:
 - Saline wash of the wound
 - Removal of foreign bodies
 - Dress the wound and put the hand in a volar splint
- Exploration of the laceration and repair ruptured tendons
- Postoperative hand protocol for flexor tendon injuries

Complications

- Arterial injuries
- Nerve injuries
- Infections
- Rupture of repaired tendon
- Adhesions
- Late flexion deformity

1.9.14. Nerve Injuries

Definition: Rupture or contusion of nerves.

Causes

- Penetrating injuries
- Compression neuropathies

Signs and symptoms

(Will depend on which nerves are involved and at which level it is injured)

- Numbness
- Pain
- Weakness
- Twitching
- Sensitivity

- Paralysis
- High radial palsy: loss of extension of wrist and fingers
- Low radial palsy: extension of wrist is preserved
- High median palsy:
 - Paralysis of long flexors of the thumb, index and middle finger
 - Loss of thumb opposition
 - Paralysis of pronator teres
- Low median palsy:
 - Power loss of thumb opposition
 - Loss of skin sensation to the palmar surfaces of the thumb, index and middle finger
- Low ulna palsy:
 - Paralysis of most intrinsic muscles of the hand causing:
 - Loss of adduction and abduction of fingers
 - Loss of precision movement of fingers
 - Loss of sensation to ring and little fingers
 - Clawing deformity
- High ulna palsy: It is similar to low ulna palsy except that there is no clawing deformity

Investigations

- FBC
- Plain x-ray
- EMG (Electromyography)

Management

- For non penetrating injuries, follow up patients for 3 months to rule out neuropraxia which will recover spontaneously.
- For penetrating injuries, if nerve injury is suspected, refer the patient to a unit that can explore the wound and repair damages.

Complications

- Associated arterial injuries
- Paralysis
- Neuromas
- Hyper or hyposensitivity

1.9.15. Vessel Injuries

Definition: Laceration to the arterial supply of the hand or fingers.

Causes

- Penetrating injuries
- Fractures

Signs and symptoms

- Profuse bleeding
- Pain
- Compartment syndrome
- Sluggish capillary filling
- Cold hand
- Loss of sensation (associated nerve injury)

Investigations

- FBC
- Plain x-ray

Management

- What to do in case of profuse arterial bleeding:
 - Follow ATLS protocol
 - Elevate the hand
 - Put a tourniquet proximal to the laceration
 - Explore the wound or put a compressive dressing just on the spot that is bleeding just enough to control bleeding
 - Remove the tourniquet
 - Take the patient to theater for selective ligation of the artery or its repairIf Compartment Syndrome is suspected, do compartment release with appropriate fasciotomy.

Complications

- Associated nerve injuries
- Compartment Syndrome
- Loss of hand or finger (Gangrene)

1.9.16. Skin defects

Definition: Loss of skin tissue.

Causes

- Burn
- Trauma
- Tumor excisions
- Debridement

Signs and symptoms

- Assess the size of the defect
- Assess the depth of the defect
- Assess whether underlying vital structures are exposed or involved

Management

- If the wound can be closed without compromising the function of the hand or the anatomy of the hand, do a primary closure
- If a primary closure is not feasible and there is no underlying vital structures exposed, do a skin graft
- If underlying structures are exposed, cover with a flap
- If underlying structures are involved, repair them and cover with a flap

Complications

- Scar contractures
- Damage of vital structures

2. Neurosurgery

2.1. Spinal Cord Injuries

2.1.1. General Considerations

Definition: physical trauma to the spinal cord from craniocervical junction to the sacrococcygeal region. It may be complete or partial.

Complete: There is no neurological function below the level of the lesion.

Partial: There is preservation of some neurological function which may be motor, sensory or both.

Cervical cord injuries are divided into two namely high cervical and low cervical injuries.

High cervical injuries are from C3 and above and are associated with high mortality rates due to the phrenic nerve being cut off (C3, 4 and 5 that results in respiratory failure)

Low cervical injuries are from C5 and below

Spinal shock is the transient loss of neurological function and evidence is flaccid paralysis and areflexia that may last up to 2 weeks

Causes

- Trauma
- Tumors
- Infections
- Vascular conditions

Signs and symptoms

Complete

- High cervical injury; most of the patients will die at the scene of the accident because of respiratory failure
 - Gasping for air
 - Urinary retention
 - Reduced GIT function

- Low cervical injury
 - Low BP due to sympathetic cut off
 - Abdominal breathing
 - May have upper limb function e.g. injury at C7 will be able to lift arms
 - Extremities are warmer than usual with dilated vessels

Partial

- Partial Cord injuries are composed of the following syndromes
 - Central Cord Syndrome: greater motor deficit in upper limbs than lower limbs
 - Brown Sequard (Cord hemisection) Syndrome: motor paralysis and loss of proprioception and vibratory sense ipsilateral to the lesion with loss of pain and temperature sensation contralateral to the lesion 1 or 2 segments below
 - Anterior Cord Syndrome: loss of motor function with preservation of proprioception and vibratory sensation
 - Posterior Cord Syndrome: loss of proprioception and vibratory sensation with preservation of motor function

Investigations

- FBC, CRP and ESR etc. when suspecting infection
- X-rays and CT scan may show the bony cause of spinal cord injury
- Myelography with or without CT scan, indicated for people that have contra indication for MRI
- Investigation of choice is MRI

Management

- For spinal trauma manage according to ATLS (Adult Trauma Life Support)
- Put cervical collar
- Hard board for thoracic and lumbar suspected injuries (Prevent pressure sores)
- For blunt trauma give Methyl prednisolone 30mg/kg IV for 30min and rest for 30min give 5mg/kg/hr 23 hours for those seen within first 5 hours of injury and for 48 hours for those seen between 5 - 8 hours of injury
- After making diagnosis treat accordingly

- Patients should have immediate decompression where there is cord compression by a neuro surgeon or any other trained surgeon in doing the procedure

Complications

- Pressure sores
- Respiratory Tract Infections
- Urinary Tract Infections
- DVT
- Pulmonary embolus

Recommendation

- Complications are best managed by anticipatory preventive measures.

2.1.2. Spinal Fractures and Dislocation

Definition: Refers to disruption of vertebra column caused by physical trauma. Fractures may be stable or unstable. Stable fractures are those with minimal or no risk of neurological damage whereas unstable fractures are those with a high likelihood of neurological damage coupled with slight movement.

Causes

- Motor accidents
- Fall from height
- Sports injuries
- Projectiles

Specific types of fractures

- C1 - Jefferson
- C2 - Odontoid fractures (Types 1,2and 3)
- Hangerman's fractures
- Subaxial spinal injuries
 - Single facet dislocation
 - Bifacet dislocation
- Thoracic
 - Upper
 - Middle
 - Thoraco lumber

- Lumbar
 - Wedge compression fractures
 - Burst fractures
 - Fracture dislocations
 - Seatbelt fractures

C1 Fractures

There are three types of C1 fractures, types I to III, the most common is type II (Jefferson)

C1 - JEFFERSON

Definition: It is a burst fracture of C1 ring; at 2 or more points on C1 ring

Cause

- Loading force directly over the head (in neutral position)

Signs and symptoms

- History suggestive
- Neck pain
- Neurological deficits are rare

Investigations

- X-ray of C spine
- C T scan (best choice)
- MRI

Management

- Analgesia
- Hard collar or SOMI brace (Sternal Occipital Mandibular immobilization)
- Surgical intervention indicated when there is disruption of transverse ligament

C2 - FRACTURES

ODONTOID FRACTURES

- Type 1: fracture through the tip
- Type 2: fracture through the base of odontoid
- Type 3: involves both odontoid and body of C2

Causes

- Motor accidents
- Fall from height
- Sports injuries
- Projectiles

Signs and symptoms

- High posterior cervical pain sometimes radiating to occipital region
- Paraspinal muscle spasm
- Reduced range of motion of the neck
- Tenderness to palpation over the upper cervical spine
- Tendency to support the head with the hands
- Paraesthesias in upper limbs

Investigations

- C – x-ray with open mouth views
- CT scan

Management

- Type1: The most common is immobilization with SOMI brace or hard collar. Sometimes needs surgery because of associated ligamentous injury
- Type 2: If there is displacement of more than 4mm surgery is needed
- Type 3: Treated by immobilization with SOMI brace or hard collar for 6 -12 weeks

HANGERMAN'S FRACTURES

Description: Bilateral fracture through the pars interarticularis with traumatic subluxation on C2 and C3, most of them are stable with no neurological deficits. It has three types which are: type1, type2, type 3 (Levine classification), type 1 is stable; types 2 and 3 are unstable.

Causes

- Motor accidents
- Fall from height
- Sports injuries
- Projectiles

Signs and symptoms

- Neurologically intact if any they are minor
- Neck pain
- Commonly associated with head and cervical injuries

Investigations

- X-rays
- CT scan with CTA (CT angiography)
- MRI/MRA (MR angiography)

Management

- SOMI brace or hard collar for 8- 14 weeks
- For Type 2 may require closed reduction with external immobilization
- Type 3 requires ORIF

2.1.3. Subaxial Spinal Injuries (from C3 – C7)

Types

- Unifacet subluxation (Jumped facet)
- Bifacet subluxation

UNIFACET SUBLAXATION

Description: Commonly associated with less neurological deficit, the affected facet has its capsule disrupted.

Cause

- Flexion and rotation of the neck

Signs and symptoms

- Neck pain
- Neurological deficit

Investigations

- C – spine x-rays
 - AP view spinous process above subluxation they rotate to the same side of the jumped facet
 - Lateral view shows bow tie sign (visualization of left and right facet joint instead of usual superimposed position)
 - Oblique view may demonstrate jumped facet blocking neuro foramen
- CT scan shows naked facet sign (reversed Hamburg sign)
- MRI to rule out disc prolapsed

Management

- Initial treatment may be open or closed reduction.

BIFACET SUBLAXATION

Descriptions: Occurs with disruption of ligaments of apophysial joints, ligamentum flavum, longitudinal and interspinous ligaments and annulus, most common at C5/ C6 or C6/C7, associated with 65-87% complete quadriplegia.

Causes: Hyperflexion of the neck.

Signs and symptoms

- Associated with 65- 87% complete quadriplegia
- 15-25% may have incomplete quadriplegia

Investigations

- C spine x-ray (lateral view show a vertebral body over the adjacent one)
- CT scan
- MRI to rule out prolapsed disc

Management

- Closed reduction by putting patient on prolonged tongs traction
- ORIF

2.1.4. Spinal Cord Injury Without Radiographic Abnormality (SCIWORA)

Description: It happens in a subgroup of children with neurological deficits, but radiographic investigations show no abnormality (both static and dynamic). This is attributed to normally increased elasticity of the spinous ligaments and intervertebral soft tissue in young population.

Causes

- Motor accidents
- Fall from height
- Sports injuries
- Projectiles

Signs and symptoms

- Gasping for air
- Urinary retention
- Reduced GIT function
- Low BP due to sympathetic cut off
- Abdominal breathing
- May have upper limb function e.g. injury at C7 will be able to lift arms
- Extremities are warmer than usual with dilated vessels

Investigation

- MRI is the investigation of choice

Management

- Commonly supportive
- Surgical intervention has shown no improved outcome

2.1.5. Thoracic Fractures

Description: The thoracic canal is smaller compared to other spinal regions making it more vulnerable to even small compressive lesions. Having a ribcage makes it more rigid and less susceptible to unstable fractures. It is commonly associated with chest injuries.

Causes

- Motor accidents
- Fall from height
- Sports injuries
- Projectiles

Signs and symptoms

- Bruising around the area
- Tenderness on affected area
- Bump along the spine
- Partial or complete paraplegia
- Bladder and bowel dysfunction

Investigations

- Thoracic x-rays
- CT thoracic spine
- MRI

Management

- Initial assessment and management according to ATLS
- Definitive treatment in specialized centres

2.1.6. Thoracolumbar Fracture

Description: Thoracolumbar fracture is a transition zone between the rigid thoracic spine and mobile lumbar spine. It is between T10 to L2. This is among the most commonly susceptible regions to fractures.

Common Types of fractures

- Compression fractures
- Burst fractures
- Seat belt fractures
- Fracture dislocation

COMPRESSION FRACTURES

Definition: It's a wedge compression of the anterior part of the vertebral body.

Cause

- Flexion injury to thoraco lumbar region

Signs and symptoms

- Bruising around the area
- Tenderness on affected area
- Bump along the spine

Investigations

- Plain thoracolumbar x-rays (AP &Lateral Views)
- CT Scan

Management

Indications for surgery

- Wedge pointing
- Excessive Kyphosis
- When there are 2 or more contiguous fractures
- If there is any neurological deficit
- Progressive kyphosis

Recommendations

- Bed rest
- Analgesia
- TLSO (Thoracolumbar sacral orthosis)

BURST FRACTURES

Description: There is a pure axial loading force leading to compression of the vertebral body.

Causes

- Motor accidents
- Fall from height
- Sports injuries
- Projectiles

Signs and symptoms

Will depend on patency of the spinal canal

- Severe pain
- Tenderness to palpation
- Bruising
- May or may not have neurological deficit (50 % of patients will remember some form of neurological dysfunction, that subside during transfer to hospital)

Investigations

- X-rays
 - Lateral x-rays show; cortical fracture of posterior VB
 - retropulsion of bone fragments into canal
 - AP View show increase in interpedicular distance, laminae fractures, spraying of facet joints
- CT scan
- MRI

Management

- Manage according to ATLS protocol
- Specialized surgical intervention

SEATBELT FRACTURES

Definition: It's a flexion injury sustained on a fulcrum which may be bony, ligamentous or both. It has four subtypes, type I is called a *chance fracture* (purely through bone).

Causes

- Motor accidents
- Seatbelt injuries
- Fall from height
- Sports injuries
- Projectiles

Signs and Symptoms

- Severe pain
- Tenderness to palpation
- Seatbelt bruising
- Abdominal injuries
- May or may not have neurological deficit

Investigations

- X-rays
- CT scan
- MRI

Management

- Manage according to ATLS
- TLSO in extension for patients with no neurological deficit
- Specialized surgical intervention

FRACTURE DISLOCATION

Description: It is due to failure of the three columns due to compression, tension, rotation or shear leading to subluxation or dislocation. It is the worst type of a thoracolumbar fracture.

Causes

- Fall from height
- Motor accidents
- Sports injuries
- Projectiles

Signs and symptoms

- Severe pain
- Tenderness to palpation
- May have abdominal injuries
- Neurological deficit

Investigations

- X-rays
- CT scan
- MRI

Management

- Manage according to ATLS
- Specialized surgical intervention

2.1.7. Cauda Equina

Definition: It is a clinical condition arising from dysfunction of multiple lumbar and sacral nerve roots compression within lumbar spinal canal. Usually due to compression of cauda equina.

Causes

- Massive herniated lumbar disc
- Tumors
- Free fat graft following discectomy
- Trauma
- Spinal epidural hematoma
- Infection e.g. epidural abscess, septic thrombophlebitis
- Neuropathy (inflammatory or ischemic)
- Enkylosing spondylitis

Signs and symptoms

- Sphincter disturbance
- Saddle anesthesia
- Significant motor weakness (usually involves more than a single nerve root if not treated may progress to paraplegia)
- Bilateral absence of Achilles reflex
- Low back pain and/or Sciatica usually bilateral
- Sexual dysfunction

Investigations

- Infection screening
- X-ray
- CT scan
- MRI

Management

- Surgical intervention in specialized centers in case of compression, which must be performed within 24 hours
- Conservative management in case of inflammatory and ischemic neuropathies

Complications

- Paraplegia
- Persistent sphincter dysfunction
- Pressure sores
- Urinary infection
- DVT

2.2. Cerebral Vascular Diseases (Spontaneous Haemorrhage)

Intracranial hemorrhage may be subdural, subarachnoid and intracerebral (intra parancyma). Subdural hemorrhage is discussed under traumatic causes of intracranial hemorrhages.

2.2.1. Intracerebral Hemorrhage

Definition: It is a hemorrhage within the brain parenchyma, commonly referred to as hypertensive hemorrhage, it is the second most common form of strokes (15-30%) but most deadly. Occurs at common sites for hypertensive bleeds (putaminal, thalamic, cerebellar and lobar).

Risk Factors

- Age (> 55yrs)
- Gender common in females
- Previous stroke
- Alcohol consumption
- Drug abuse
- Cigarette smoking
- Liver dysfunction

Causes

- Chronic poorly treated hypertension
- Amyloid angiopathy
- Ischaemic transformation
- Rupture of an aneurysm
- AVM (arterio Venous malformation)
- Coagulopathies
- Tumors
- Idiopathic

Signs and symptoms

- Headache of sudden onset
- Gradual neurological deterioration (consciousness, slurred speech, extremity weakness)

Causes

- Hypertension
- Trauma

Investigations

- Coagulation screen (LFTs, PI/PTT or INR etc)
- RFTs
- Glycemia
- ECG
- CT scan without contrast
- CT angiography in suspicious cases (AVM, aneurysm)
- MRI (Not necessary in acute phase)

Management

- Manage according to ACLS (Advanced Cardiac Life Support)
- Manage specific to cause:
 - Aneurysm (see Sub Arachnoid haemorrhage (SAH))
 - AVM; do clipping or embolization or both
- Control hypertension by 20% of initial systolic pressure
- Admit comatose patients to ICU (GCS = 9 < from 13-10 to HDU)
- Control and maintain Euglycemia, Euvolaemia
- Normal temperature
- Anticonvulsants
- Medical Control of intracranial hypertension

Guidelines for considering surgery versus medical management

Non surgical

- Minimally symptomatic lesions (GSC >10)
- Situations with little chance of good outcome such as poor prognostic factors such as: renal failure, heart failure, poor neurological dysfunction etc.
- Severe coagulopathies
- Basal ganglia or thalamic hemorrhage

Surgical

- Lesion with marked mass effect, oedema, midline shift
- Lesions where symptoms appear to be due to increases ICP
- Volume of hematoma (Types minor < or = 10mls, moderate 10-30mls, severe > 30mls) surgery is indicated for moderate volumes
- Cerebellar hematomas surgery is indicated for hematomas > or = 3cm in widest diameter
- Failure of medical management
- Rapid deterioration regardless of hematoma location and size
- Favorable location e.g. lobar, cerebellar, external capsule and non dominant hemisphere
- Age less than 50yrs
- Early intervention (less than 24 hours)

2.2.2. Subarachnoid Hemorrhage

Description: It occurs as a result of bleeding from aneurismal rupture in 5% from perimesencephalic.

Causes/Risk factors

- Hypertension
- Smoking
- Excessive alcohol consumption

Signs and Symptoms

- Sudden onset of headaches (described as the worst headache of my life)
- Nausea and vomiting
- Photophobia
- Neurological dysfunctions
- Seizures

Investigations

- Coagulopathy screen
- CT Scan without contrast
- CTA

Management

Management is based on grade of patient

PATIENT GRADING (WFNS SAH grading)

Grade	GCS	Focal neurological deficit
I	15	Absent
II	13-14	Absent
III	13-14	Present
IV	7-12	Present or absent
V	<7	Present or absent

General measures

- Fluids additional 3l to the usual maintenance
- Adequate analgesia
- Elevate head to 30°
- Quiet rooms and dim light
- Anticonvulsants
- Stool softeners
- Nimodipine 60mg Per Os every 4 hours for 21 days or when aneurysm is clipped
- Aneurysm clipping or coiling (specific measure)

Complications

- Vasospasms occurs between day 3 – 14
- Treated with hydration and Nimodipine
 - Hydrocephalus which can occur immediately or after

2.3. CNS Infections and Infestations

2.3.1. Brain Abscess

Definition: Is a pus containing cavity in brain, it goes through stages.

Causes

- Hematogenous spread
- Contagious spread

Signs and symptoms

- Direct inoculation
- Non specific signs
- Fever
- Headache
- Nausea
- Lethargy
- Neurological deficit
 - Papilloedema
 - Seizures

Investigations

- Infection screen
- CT scan with contrast

Complications

- Seizures
- Permanent neurological deficit

Management

Management may be medical alone or medical with surgical drainage/ surgical excision

Medical management

- Fluid resuscitation
- Anticonvulsants
- Antibiotics

Note:

ICU admission may be necessary depending on GSC

2.3.2. Cranial Subdural Empyema

Definition/Description

SUBDURAL EMPYEMA: A collection of pus in subdural space.

CRANIAL EPIDURAL EMPYEMA: A collection of pus between bone and duramater

Causes

- Hematogenous spread
- Contagious spread
- Direct inoculation

Signs and symptoms

- Swelling on the fore head (Pott's puffy tumor)
- Non specific signs
- Fever
- Headache
- Nausea
- Lethargy
- Neurological deficit
- Papilloedema
- Seizures

Investigations

- Infection screen
- CT scan with contrast

Complications

- Seizures
- Permanent neurological deficit

Management

Management may be medical alone or medical with surgical drainage

Medical management

- Fluid resuscitation
- Anticonvulsants
- Antibiotics
- ICU admission may be necessary depending on GSC

2.3.3. Neuro Cysticercosis

Definition: it is intracranial encasement of larva of *T solium*, it is the most common parasitic infestation in CNS.

Mode of transmission

- Water and food contaminated with eggs
- Fecal oral
- Auto infection

Signs and symptoms

- Seizures
 - Signs of Raised ICP
 - Focal neurological deficits
 - Subcutaneous nodules

Investigations

- Serology or CSF (Antibody or antigen of Cysticercosis)
- CT scan or MRI

Management

- Antihelminthic (e.g. Albendazole 15mg /kg/d PO in divided or single dose for 21 days or praziquantel)
- Steroids (e.g. Dexamethasone 2-4 mg PO every 8 hours for 2weeks)
- Anticonvulsants (e.g. Phenytoin 15-20mg /kg as a loading dose and maintenance dose of 5mg/kg/day for 21 days or as long as seizures are present)
- Surgery; excision of the cyst

Indications for surgery

- Large cysts causing mass effect
- Cysts causing obstructive hydrocephalus

2.4. Hydrocephalus in Children

Description: It is a condition that results when normal exit and absorption of cerebral spinal fluid in the ventricles are impaired. This leads to progressive accumulation of this fluid in the ventricles of the brain, resulting in progressive damage to the developing brain with associated mental retardation and visual impairment.

Causes

- Congenital abnormality
- Intraventricular hemorrhage
- Infection
- Head trauma
- Brain tumor

Signs and symptoms

- Accelerated head growth
- The baby's soft spot (anterior fontanelle) is usually full or bulging, or even tense, due to the increased pressure inside the head.
- Sometimes the baby's eyes will appear to be looking downward all the time (sunset phenomenon), or may look crossed.

Investigations

- Serial measurement of head circumference which shows excessive head growth
- Ultrasound study of the brain can be performed
- CT scan of the brain
- MRI of the brain

Complications

- Permanent blindness
- Permanent psychomotor disability
- Shunt complication (malfunction)
- Infection

Management

- Ventriculo-peritoneal shunt insertion is the most commonly used
- Endoscopic third ventriculostomy
- Treatment of the cause in case of obstructive hydrocephalus

2.5. Myelomeningocele

Definition: Congenital defect in vertebral arches with cystic dilatation of meninges and structural or functional abnormality of spinal cord or cauda equina.

Risk factors

- Low folate during female reproductive age
- Obesity
- Smoking
- Alcohol use
- Anticonvulsants
- Febrile illness, heat exposure, hot tub and sauna during first trimester
- Genetic
- Young age

Signs and symptoms

- Non skin covering spinal defect with fluid containing cyst
- Neurological dysfunction below the level of lesion
- Lower limb deformities such as club feet
- Chiari type 2 malformation and hydrocephalus may be associated

Investigations

Prenatal

- Amniocentesis
- Ultrasound

Postnatal

- CT scan
- MRI

Management

- Early closure of myelomeningocele defect by a trained surgeon
- Infection prophylaxis with ceftriaxone or cefotaxime and gentamycin immediately for 1 week
- Covering of spinal defect with a sterile saline soaked gauze which can be changed as needed
- Monitor head circumference and anterior fontanel for possible development of hydrocephalus

Complications

- Permanent neurological deficit
- Pressure sores
- Urinary tract infection
- Meningitis
- Ventriculitis
- Hydrocephalus

2.6. Head Injury

Definition: Head injury is physical trauma to the head. It is broadly classified into 2 entities:

- Open head trauma in which there is a scalp laceration with underlying skull fracture and breached Dura Mater (i.e. brain communication to the outside environment).
- Closed head injury – there is no communication with the outside environment.

It can also be classified by severity into mild, moderate and severe head trauma depending on the level of consciousness.

Causes

- Motor Vehicle Accidents (MVA)
- Pedestrian Vehicle Accident (PVA)
- Assault injuries
- Fall from heights
- Sports injuries
- Missile injuries e.g. gunshot wounds

Signs and symptoms

- Deterioration of level of consciousness (GCS)
- Seizures
- Vomiting
- Headache
- Evidence of skull base fracture such as :
 - Raccoon eyes (peri-orbital ecchymoses)
 - Battles sign which are post auricular ecchymoses
 - CSF rhinorrhoea
 - Otorrhoea
 - Haemotympanium
- Wounds or hematoma on impact site
- Focal neurological deficit such as hemiplegia

SEVERITY ASSESMENT OF HEAD TRAUMA

- Divided into 5 categories:
- Minimal : here GCS =15,no Loss of consciousness (LOC)
- Mild: GCS = 14 or GCS = 15 with either brief LOC of < 5 minutes, or impaired alertness or memory
- Moderate: GCS=9-13 or LOC > 5minutes or Focal Neurological Deficit
- Severe : GCS =5-8
- Critical : GCS = 3-4

Investigations

- RBG, FBC, PT, PTT, Blood Grouping and Cross Matching
- Urea and Electrolytes
- Toxicology screening e.g. alcohol, illicit drugs screening
- Arterial Blood Gas Levels are very important
- Skull x- ray to look for fracture
- Brain CT scan

Management

- The Primary goal of therapy is to prevent secondary brain injury which is done by maintaining adequate perfusion and ventilation.
- After following ATLS guidelines for management of trauma patients, management follows the severity of the head trauma.
- Mild head trauma
 - Bed rest with head off bed (HoB) elevated to 30-45 degrees
 - Neuro checks every 2 hours or every hour if more concerned
 - NPO until alert, then clear fluids and advance to other foods as tolerated
 - Isotonic IV fluids mainstay being N/Saline running at usually 100mls/hr
 - Mild analgesia: paracetamol PO or PR if NPO
- Moderate head trauma
 - As in minor above but always keep NPO in case surgical intervention is needed
 - GCS 9-12 ADMIT to ICU, GCS 13 ADMIT IF CT shows any significant abnormality
 - Patients with normal or near normal CT-Scans should improve within hours. Any that fails to reach GCS 14-15 with in 12 hours should have the CT repeated at that time.

SEVERE AND CRITICAL HEAD INJURY

These are usually co- systemic injuries. They are admitted to ICU and the first priority is to look for any features of Intra-Cranial Hypertension (IC-HTN) which are:

- Unilateral or bilateral pupillary dilatation
- Asymmetric pupillary reaction to light
- Decerebrate or decorticate posturing
- Progressive deterioration of neurological sign not attributable to extra cranial factors

When one or more of these signs is witnessed in evolution, that's convincing evidence of IC-HTN

These patients have to be:

- **INTUBATED** - with a GCS of 8 or less it's assumed one cannot keep the patient's airway patent. Patients with severe maxillofacial injury will also need to be given a tracheostomy.
- **HYPERVENTILATION** - only when a patient has CT and clinical features of IC-HTN should they be hyperventilated, and the PCO₂ should be between 30-35 mmHg and should never drop below 30mmHg - this is a temporary measure awaiting definitive treatment for the IC-HTN
- **PARALYSIS AND SEDATION** - only when there is evidence of IC-HTN should there be paralysis and sedation
- **MANNITOL** - is given only in cases of:
 - Evidence of IC-HTN
 - Evidence of mass effect e.g. focal deficits like hemi paresis
 - Sudden deterioration prior to CT-Scan
 - If a lesion associated with increased ICP is identified e.g. SDH, EDH
 - Assess the recovery ability of patients with no evidence of brain stem function (look for return of brain stem reflexes)

It is contraindicated in hypotension (map 70mmhg) but remember that when one is resuscitated and the BP is acceptable then mannitol can be given.

Mannitol should be used with caution in patients with clotting disorders because it affects coagulation, and in congestive heart failure patients it increases intravascular volume before it causes diuresis.

DOSE: bolus with 0.25 – 1gm/kg over 20mins.

Remember steroids (dexamethasone, hydrocortisone) have no place in management of acute head injury.

- **PROPHYLACTIC ANTI-EPILEPTIC DRUGS:**

Given when there is increased risk of Post Traumatic Seizures namely:

- Acute SDH, epidural and intracerebral haematoma
- Open depressed skull fractures with parenchymal injury
- Seizure within the first 24 hours of injury
- GCS less than or equal to 10
- Penetrating brain injury
- History of significant alcohol intake
- Cortical (hemorrhagic) contusion on CT-Scan

Preferred drug is PHENYTOIN (EPANEUTIN) loading dose of IV drug 18mg/kg in 200mls of N/Saline to run within 30mins for the 1st 24 hrs then maintenance of 5mg/kg daily on subsequent days.

- **SURGERY:** Is indicated to evacuate any haematomas that are the cause or potential cause of IC-HTN and is only done when the patient has been stabilized.

Complications

- Post-traumatic seizures
- Permanent neurological disability
- Post-traumatic hydrocephalus
- Post-Concussion Syndrome
- Infection e.g. Meningitis, brain abscess, chronic osteitis etc.
- Chronic traumatic encephalopathy
- Subdural hematoma
- It is a collection of blood between the Dura Mater and arachnoid layer. It is subdivided into acute (< 72hours) Subacute (between 72 hours and 3 weeks) and Chronic (> 3weeks).
- The most commonly seen are acute and chronic subdural hematoma

2.6.1. Acute Subdural Hematoma

Causes

- Fall
- Motor vehicle accident
- Assault
- Child abuse (Shaken Baby Syndrome)

Signs and symptoms

- Coma, vomiting
- Brain herniation signs such as dilated ipsilateral pupil
- Hemiparesis

Investigations

- Fundoscopy in case of Shaken Baby Syndrome (retinal hemorrhage can be evidenced)
- CT scan (to visualize crescentic hematoma and midline shift)

Management

- General management of head injury
- Indications for surgery
 - Subdural hematoma thickness greater than 10mm
 - Midline shift greater than 5mm as seen on CT scan
 - Less of the above but with decreasing of GCS between the time of injury and hospital by 2 or more points or fixed and dilated pupils and or ICP exceeds 20mmHg

2.6.2. Chronic Subdural Hematoma

Cause

- Minor head injury or fall often not remembered by patients or relatives.

Risk factors

- Old age
- Alcohol abuse
- Seizures
- Cerebral spinal fluid shunts
- Anticoagulation

Signs and symptoms

- Headache
- Nausea
- Vomiting
- Hemiparesis
- Language disturbances
- Gait problems
- Transient ischemic attack like symptoms
- Decreased consciousness
- Sphincter disorder
- Bilateral papilloedema on funduscopy

Investigations

- Coagulation screening
- ECG
- CT scan which shows hypo or isodense fluid collection in crescentic shape and midline shift
- MRI

Management

- Stabilization of patients according to ACLS protocol
- Surgery by a trained surgeon

2.6.3. Epidural Hematoma

Definition: It is the collection of blood between the skull and the Dura Mater caused by a rupture of artery and vein in epidural space, as a result of a fracture of the skull at the moment of the impact in 60-90% of cases.

Causes

- Motor Vehicle Accidents (MVA)
- Pedestrian Vehicle Accident (PVA)
- Assault injuries
- Fall from heights
- Sports injuries

Signs and symptoms

- Neurological presentation varies according to the size, location and time course of the hematoma
- Lucid interval is common
- Vomiting
- Hemiparesis
- Brain Herniation Syndrome

Investigations

- X-ray can show the fracture of the skull
- CT scan can show biconvex shaped hematoma adjacent to the skull

Management

- Initial management according to ATLS
- Epidural hematoma in posterior fossa and temporal region are especially dangerous
- Surgical treatment is commonly indicated to remove hematoma as soon as possible

Complications

- Permanent neurological deficit
- Prolonged coma leading to pressure sores, DVT, pulmonary and urinary infection

2.6.4. Intracranial Hematoma

Definition: Traumatic intraparenchymal hemorrhage is commonly associated with brain contusion.

Causes

- Motor Vehicle Accidents (MVA)
- Pedestrian Vehicle Accident (PVA)
- Assault injuries
- Fall from heights
- Sports injuries
- Missile injuries

Signs and symptoms

- Focal neurological deficit according to the sites
- Alteration of consciousness
- Seizures
- Vomiting
- Traumatic lesions on site of impact
- Herniation Syndrome

Investigations

- X-ray shows bone lesion or intracranial foreign bodies in case of penetrating injury
- CT scan is the investigation of choice

Management

- Initial management is according to ATLS protocol
- Surgery is indicated in:
 - Progressive neurological deterioration referable to the TICH, medically refractory intracranial hypertension or signs of mass effect on CT Scan
 - TICH > 50ml
 - GCS = 6-8 with frontal or temporal TICH volume > 20ml with midline shift \geq to 5mm and/or compressed basal cisterns on CT

Complications

- Post-traumatic seizures
- Permanent neurological disability
- Post-traumatic hydrocephalus
- Prolonged coma leading to pressure sores, DVT, pulmonary and urinary infection

3. Cardio Thoracic Surgery

3.1. Chest Trauma

3.1.1. Simple Rib Fracture

Definition: Simple rib fracture is a break in continuity of the rib(s).

Causes

- Pathological
- Injury to the chest

Signs and symptoms

- Chest pain
- Difficulty breathing
- Chest wall wound (bruise, contusion or laceration)
- Shallow and rapid breathing
- Localized tenderness on palpation
- Altered percussion note
- Reduced breath sound on auscultation

Investigations

- CXR
- CT scan and MRI

Management

- Admit the patient
- Analgesics for pain control
 - local infiltration using 2% lignocain)
 - SC morphine according to patient body weight
 - NSAID (ibuprofen or diclofenac either oral or per rectal)
- Chest physiotherapy

Complications

- Atelectasis
- Pneumonia

3.1.2. Flail Chest

Definition: Segmental fracture of rib(s) resulting in paradoxical movement of the chest that may lead to respiratory dysfunction.

Cause

- Trauma to the chest

Signs and Symptoms

- Chest pain
- Difficulty in breathing
- Paradoxical chest movement
- On inspection - bruising, contusion or laceration of the chest wall
- On palpation - localized tenderness
- On auscultation - reduced breath sounds

Investigations

- CXR
- CT scan and MRI

Management

- Admission
- High flow oxygen by mask
- Position patient on the injured side
- Analgesia
- Restricted fluid administration
- Monitor oxygen saturation
- Intubate if patient not responding
- Admit to ICU for mechanical ventilation

Complications

- Associated injuries (lung contusion, haemothorax, pneumothorax and pericardial tamponade)
- Pneumonia
- Empyema thorasis

3.1.3. Pneumothorax

Definition: Collection of air in pleural cavity which can be either simple or under tension resulting in pressure on the mediastinum.

Causes

- Chest trauma
- Spontaneous

Signs and Symptoms

Tension pneumothorax

- Chest pain
- Bruising, contusion, laceration of chest wall
- Severe dyspnea
- Cyanosis
- Mental confusion
- Sweating
- Reduced chest movement
- Displacement of the tracheal and apex beat
- Absent breath sounds on affected side
- Hyperresonance
- Hypotension
- Jugular venous distension

Simple pneumothorax

- Chest pain
- Shallow respiration
- Bruising, contusion, laceration of chest wall
- Reduced breath sounds
- Heperresonance

Investigations

- Clinical diagnosis for tension pneumothorax
- CXR, CT scan for simple pneumothorax

Management

Tension pneumothorax

- Wide bore cannula in the second intercostals space mid-clavicular line
- High flow oxygen by mask
- Analgesia for pain
- Monitor oxygen saturation
- Chest tube insertion with underwater seal connection

Simple pneumothorax

- High flow oxygen by mask
- Analgesia
- Monitor oxygen saturation
- Chest tube insertion under water seal connection

Complications

- Collapse lung
- Lung contusion
- Pneumonia

3.1.4. Haemothorax

Definition: The collection of blood in pleural space.

Cause

- Chest trauma

Signs and symptoms

- Chest pain
- Bruising, contusion, laceration of chest wall
- Dyspnea
- Sweating
- Hypotension
- Diminished breath sound
- Dull percussion note

Investigations

- CXR
- CT scan

Management

- High flow oxygen by mask
- Analgesia
- Chest tube insertion under water seal connection
- May transfuse
- Thoracotomy may have to be done if initial drainage is more than 1.5 L of blood or if active drainage is more than 200 ml/ hour

3.1.5. Cardiac Tamponade

Definition: The collection of blood in pericardium causing cardiac dysfunction.

Cause

- Chest trauma

Signs and symptoms

- Chest pain
- Bruising, contusion, laceration of chest wall
- Congestion of neck veins
- Hypotension
- Severe dyspnea
- Mental confusion
- Distant muffled heart sound
- On ECG there is electrical alternans
- Pulsus paradoxicus
- FAST (focused abdominal sonography in trauma); pericardial effusion

Investigations

- CXR
- CT scan
- ECG

Management

- High flow oxygen
- Analgesia
- Pericardiocentesis (sub xyphoid approach)

3.1.6. Lung Contusion

Definition: The inflammation of the lung following a chest injury.

Cause: Chest trauma

Signs and symptoms

- Chest pain
- Bruising, contusion, laceration of chest wall and rib fractures
- Dyspnea
- Reduced breath sound
- Dull percussion note
- Hemoptysis

Investigations

- CXR
- CT scan

Management

- High flow oxygen
- Analgesia
- Restricted fluid administration
- Monitor oxygen saturation
- Intubation and mechanical ventilation if not responding to the above
- May require chest drainage if associated pneumothorax and haemothorax.

3.1.7. Ruptured Diaphragm

Definition: A tear in the diaphragm which allows protrusion of abdominal organs in the chest.

Cause

- Trauma

Signs and symptoms

- Asymptomatic
- Abdominal and chest pain
- Dyspnea
- Hypotension
- Decreased breath sound
- Dull percussion note
- Bowel sound in the chest

Investigations

- CXR
- CT scan

Management

- High flow oxygen
- Analgesia
- Surgical intervention after stabilization

3.2. Lung Conditions

3.2.1. Empyema Thoracis

Definition: The collection of pus in the pleural cavity. It can be classified as acute, sub-acute and chronic.

Causes

- Partilly treated pneumonias
- Neglected pneumonias
- Pulmonary tuberculosis
- Hematogenous spread from distant foci
- Post traumatic chest infections
- Perforated oesophagus
- Local spread from sub-diaphragmatic abscess

Signs and symptoms

Acute empyema thoracis

- Chest pain
- Fever
- Sweating
- Dyspnea
- Coughing
- Underlying chest infection
- Stony dull percussion note
- Reduced breath sounds

Sub-acute empyema thoracis

- Chest pain
- Dyspnea
- Cough
- Fever
- Underlying chest infections
- Stony dull percussion note
- Reduced breath sounds
- Reduced chest movement
- Chest deformity

Chronic empyema thoracis

- Chest pain
- Cough
- Dyspnea
- Chest deformity
- Reduced chest movement

- Wasting of the chest muscles
- Stony dull percussion note
- Reduced breath sounds
- Chest wall abscess and sinuses
- Finger clubbing

Investigations

- Sputum exam
- CXR
- CT scan
- Bronchoscopy

Management

Acute empyema thoracis

- Thoracocentesis
- Chest tube drainage

Sub-acute empyema thoracis

- Chest tube drainage

Chronic empyema thoracis

- Chest tube drainage *and*
- Decortication

3.2.2. Lung Abscess

Definition: Is the presence of pus in the lung parenchyma.

Causes

- Inhalation of food particles
- Virulent pyogenic bacteria like S.Aureus and Klebsiella in a background of immune compromise

Signs and Symptoms

- Cough
- High fever
- Dyspnea
- Chest pain
- Halitosis
- Weight loss
- Finger clubbing
- Reduced breath sound
- Crepitations
- Dull percussion note

Investigations

- Sputum examinations
- CXR
- CT scan
- Bronchoscopy

Management

- Appropriate antibiotics (e.g. Clindamycin for 3 to 6 weeks)
- Chest physiotherapy
- Surgery (lobectomy)

3.2.3. Pulmonary Fibrosis and Bronchiectasis

Definition: Fibrosis of the lung following bacterial infection and/or lung abscess.

Causes

- Post pulmonary TB infection
- Pneumoconiosis
- Fungal infections (e.g. aspergilosis)

Signs and symptoms

- Cough
- Chest pain
- Dyspnea
- Loss of weight
- Finger clubbing
- Cyanosis
- Chest deformity
- Wasting of chest wall muscles
- Dull percussion note
- Crepitations

Investigations

- CXR
- Sputum examination
- CT scan
- Bronchoscopy

Management

- Treat underlying condition (TB, aspergilosis)
- Chest physiotherapy
- Symptomatic treatment
- Lobectomy or pneumonectomy

3.2.4. Lung Cancer

Definition: Malignant growth of the bronchials or parenchyma of the lung. They are divided into two groups namely; central and peripheral cancers.

Causes

- Unknown
- Predisposing factors include:
 - Smoking
 - Exposure to dusts from industrial pollution

Signs and symptoms

- Central tumors
 - Cough
 - Chest pain
 - Hemoptysis
 - Wheezing
 - Dyspnea
 - Finger clubbing
 - Loss of weight (not very common)
 - Dull percussion note
 - Crepitations on auscultation
 - Reduced breath sound
 - Metastases to other organs
 - Paraneoplastic syndromes

- Peripheral tumors
 - Cough
 - Chest pain
 - Pleural effusion
 - Dyspnea
 - Finger clubbing
 - Crepitations on auscultation
 - Reduced air entrance
 - Metastases to other organs
 - Paraneoplastic syndromes

Investigations

- CXR
- Chest and brain CT scan
- Bronchoscopy and biopsy

- Mediastinoscopy
- Pleural effusion aspiration for cytology
- Pleural biopsy

Management

- Radiotherapy
- Chemotherapy
- Surgery

3.2.5. Foreign Bodies in the Lung

Definition: Inhaled or penetrating object in the lung.

Signs and symptoms

- Inhaled object
 - Severe coughing
 - Severe dyspnea
 - Cyanosis
 - Wheezing
 - Absent or reduced breath sound
- Penetrating objects
 - History penetrating trauma
 - Cough
 - Chest pain
 - Maybe asymptomatic
 - Reduced air entrance
 - Crepitations
 - Dull percussion note

Investigations

- CXR
- CT scan
- Bronchoscopy

Management

- Inhaled foreign body is an emergency (refer to ENT section)
- For penetrating foreign body
 - If symptomatic do thoracotomy and removal
 - If asymptomatic, reassure patient and follow up

3.3. Mediastinum Masses

Definition: Space occupying lesions that may be solid or cystic located in the mediastinum compartment.

Causes

- In the superior compartment
 - Retrosternal goiter
 - Intrathoracic goiter
 - Thymoma
 - Lymphoma

- In the anterior compartment
 - Lipoma
 - Lymphoma
 - Pericardial cyst
 - MORGAGNI'S hernias

- In the middle compartment
 - Aneurysm of the ascending aorta
 - Ventricular aneurysm

- Posterior compartment
 - Neurogenic tumors
 - Enteric cysts
 - Lymphomas
 - Lymphadenopathies
 - Bronchogenic tumors
 - Oesophageal tumors

Signs and symptoms

- Signs and symptoms will depend on the type of lesion and location in the mediastinal compartments.

Investigations

- CXR
- CT scan
- MRI
- Bronchoscopy
- Mediastinoscopy

Management

- Management will depend on the type of lesion and mediastinal compartment affected.

Note:

For more information refer to relevant textbooks (Short Practice of Surgery by Bailey and Love and Principles of Surgery by Schwartz)

3.4. Congenital Diaphragmatic Hernias

Definition: Is the herniation of abdominal viscera into the chest cavity through a congenital defect of the diaphragm.

- There are two types
 - Postero- lateral hernia (Bochdalek Hernia)
 - Anterior Hernia (Morgagn's Hernia)

Cause

- Unknown

Signs and symptoms

- Bochdalek Hernia
 - They manifest at birth
 - Severe dyspnea
 - Cyanosis
 - Failure to feed
 - In drawing of the chest
 - Bowel sounds heard in the chest
 - Reduced or absent air entrance
 - Displacement of the apex beats to the right
- Morgagni's Hernia
 - It may be asymptomatic
 - Symptoms of intestinal obstruction
 - Dyspnea
 - Recurrent tachycardia

Investigations

- CXR
- Gastrografin swallow
- Abdominal x-ray
- CT scan

Management

- High flow oxygen by mask
- Intubation and ventilation
- Surgery

4. Abdominal Injuries

Definition: It is an injury to the abdomen, it may be blunt or penetrating and it may involve damage of abdominal organs.

Causes

- Blunt: road traffic accidents, falls, sports injuries
- Penetrating: stab injuries, bullet and blast injuries

Clinical features

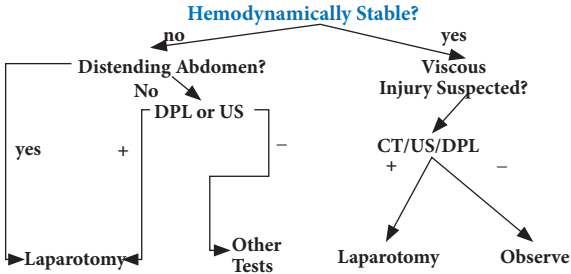
- Initial abdominal exams are often normal and may be initially asymptomatic
- Pain and tenderness increase and spread from the injury site to the other parts of the abdomen, frequently the entire abdomen
- The abdomen becomes tender, distended, and rigid
- Bowel sounds disappear
- The patient becomes progressively sicker, develops fever, and usually vomits
- Patient may fall into shock
- Respirations are shallow and rapid because it hurts to breathe deeply
- Abdominal pain is increased by moving, straightening the knees, or taking a deep breath
- The patient frequently prefers to lie quietly on his back or side with the knees flexed

Management Principles of abdominal injuries

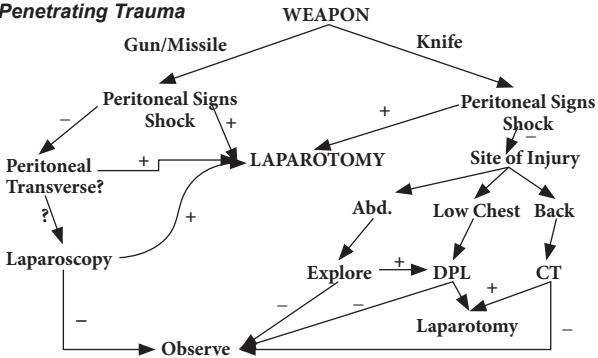
- Primary survey: The initial management of all trauma patients is to ensure an adequate air way, arrest any bleeding and restore organ circulation (ABCD evaluation)
- Secondary survey: Assessment of injury (detailed history and careful physical examination)
- Ensure early detection and decision-making on blunt abdominal injuries
- Place nasogastric tube for drainage
- Place the IV line with big calibre, administer crystalloids/colloids and take the sample for FBC
- Ensure oxygen supply
- closely monitor vital signs
- Inform theatre team to be ready accordingly

- Always inform family members and sign consent form
- Remember forensic issues (police investigation in case of weapons)

Blunt Trauma



Penetrating Trauma



4.1. Specific Injuries

4.1.1. Splenic Injury

Most can be managed non-operatively

- 90% of children
- 60% of adults

Management will depend on scale of splenic injury

- I: Hematoma or laceration (10% or 1cm)
- II: Hematoma or laceration (10-50% or 1-3cm bleeding)
- III: Hematoma or laceration (active bleeding with trabecular vessels)
- IV: Hematoma or laceration (active bleeding intraparenchymal or devascularization)
- V: Shattered or Hilar devascularization

INDICATIONS FOR OPERATION

- Hemodynamic instability (III-V)
- Acute abdomen

OPERATIVE PROCEDURE

- Splenorrhaphy
- Splenectomy (NGT in post-op is recommended to avoid any distension)

4.1.2. Hepatic Injury

Management will depend on liver injury scale

- I: Hematoma or laceration (<10 cm or 1cm depth)
- II: Hematoma or laceration (10-50% surface or 1-3cm depth)
- III: Hematoma or Laceration (bleeding and expanding or >3cm depth)
- IV: Ruptured Haematoma with active bleeding or Parenchymal disruption (75%)
- V: Parenchymal disruption >75% lobe or retrohepatic venous injuries
- VI: Hepatic Avulsion
- Most can be managed non-operatively (grade I and II)

INDICATIONS FOR OPERATION

- Hemodynamic instability
- Acute abdomen

OPERATIVE PROCEDURE

Grade I and II

- Manual compression
- Suture ligation
- Omental patch
- Closed suction drain
- Argon beam coagulation
- Topical haemostatics

Grade III to IV

- Definitive treatment or damage control
- Resectional debridement
- Perihepatic packing
- Balloon tamponade
- Foley catheter tamponade

4.1.3. Pancreatic Injury

Causes

- Often from direct blow compressing pancreas against vertebral column
- Often accompanied by duodenal injury

Investigations

- Serial serum amylase levels
- Very difficult to evaluate, even with CT
- ERCP can be helpful

Complications

- Pancreatic pseudocyst
- Duodenal or pancreatic fistula (treat with somatostatin/surgery)

Management

- Isolated injury not involving major duct: observation
- Serious injury: often involves duodenum requiring immediate exploration

4.1.4. Duodenal Injury

DUODENUM

- Often in unrestrained drivers, handlebar injuries
- Suspect with history, blood in NGT aspirate, or retroperitoneal air
- Difficult to diagnose without CT scan

OPERATIVE FINDINGS

- Upper retroperitoneal hematoma
- Bile leakage

OPERATIVE PROCEDURE

- Cattel's maneuver
- Pyoric exclusion, gastrostomy, jejunostomy

DIAPHRAGM

- Left hemidiaphragm more commonly injured
- Elevation on chest x-ray, but may be normal
- Difficult to visualize injuries by other means (including CT, MRI)
- Injuries may be missed for years

Management

- Early: laparotomy, reduce abdominal contents from chest and repair
- Late: present as diaphragmatic hernia. Reduce and repair defect in diaphragm

4.1.5. Small bowel Injury

- Can be from penetration or tearing from compression or deceleration
- Think of injury with "seatbelt sign"
- DPL good at detection transluminal injuries, but small bowel bleed minimal, may be negative
- F.A.S.T. and CT not good for small bowel

Management

- Immediate surgery
- Resection of devitalized bowel with primary anastomosis
- Stop mesenteric haemorrhage
- Peritoneal lavage

4.1.6. Colon Injury

- Immediate surgery
- Primary closure and proximal defunctioning colostomy/ileostomy
- Peritoneal lavage
- Excision and exteriorization of two ends with re-anastomosis at 3months

4.1.7. Rectal Injury

- Most often penetrating
- Can occur with pelvic fracture

Diagnosis

- Blood on examination glove
- Sigmoidoscopy

Management

- Primary repair
- +/- colostomy
- +/- pre-sacral drainage

5. Disorders of Gastro-Intestinal System

5.1. Disorders of the Oesophagus

5.1.1. Oesophageal Atresia

Definition: Congenital disorder with a blind end to the oesophagus, at first feed the infant coughs and may become cyanosed. It may be a fistula to the trachea.

Cause

- Congenital

Signs and symptoms

- Drooling, poor feeding, cyanosis, coughing, gagging, and choking with attempted feeding tube is not able to pass all the way to stomach.

Diagnosis

- Clinical

Investigations

- X-ray with contrasts of oesophagus shows an air filled pouch and air in the stomach and intestines
- Inserted feeding tube appear coiled up in the upper oesophagus
- Oesophagocopy
- Chest x-ray

Complications

- Aspiration pneumonia
- Choking and possible death
- Feeding problems
- Reflux after surgery
- Stricture of the oesophagus

Management

- Oesophageal atresia is considered a surgical emergency
- Feeding gastrostomy

- Control of electrolytes imbalance replace accordingly with corrective measures of dehydration
- Ensure nutritional support
- Good oxygen circulation
- Put the patient in the most comfortable position
- Education to the patient and the family on the management of the gastrotomy tube to avoid infection

5.1.2. Achalasia

Definition: It is a disorder of the oesophagus which affects the ability to move food towards the stomach.

Causes

- A primary neurological disorder of unknown cause
- Failure of the cardiac sphincter to relax
- Faulty peristalsis of the oesophagus due to defective parasympathetic innervations
- Cancer of the oesophagus in the upper stomach

Signs and symptoms

- Regurgitation of food
- Chest pain increasing after eating may also be felt in the back, neck and arms
- Cough
- Heart burn
- Unintentional weight loss
- Signs of anaemia or malnutrition

Investigations

- Oesophagium manometry
- Esophagogastroduodenoscopy
- Upper Gastro-intestinal x-ray with barium meal

Complications

- Regurgitation
- Aspiration pneumonia
- Perforation of esophagus

Management

- Management of achalasia aims at reducing pressure at the lower esophageal sphincter
 - Injection with Botulinum toxin to relax sphincter muscles
 - Medication such as long acting nitrates or calcium channel blockers to relax lower esophagus sphincter
 - *Surgery*: Esophago myotomy to decrease pressure in the lower sphincter
 - Dilatation of esophagus at the location of narrowing done during Esophagogastroduodenoscopy

5.1.3. Gastroesophageal Reflux Disease

Definition: It is a condition caused by retrograde passage of gastric contents into the esophagus resulting in inflammation (oesophagitis), which manifests as dyspepsia.

Signs and symptoms

- Retro sternal burning pain radiating to epigastrium
- Regurgitation of acid contents into the mouth (water brash)
- Back pain (penetrating ulcer in Barrett's oesophagus)
- Dysphagia
- Odynophagia

Investigations

- Patients over 45 years old or patients suspected of having a gastroesophageal reflux disease should be investigated, for malignancy to be excluded as a cause when symptoms of GORD are first presented.
- Barium swallow and meal: sliding hiatus hernia, esophageal ulcer, stricture
- Esophagoscopy: assess the esophagitis, biopsy for histology, dilate stricture if present
- 24 hours pH monitoring: assess degree of reflux

Complications

- Bleeding
- Reflux oesophagitis and necrosis
- Ballet's oesophagus
- Benign strictures
- Oesophagoadenocarcinoma

- Chronic cough
- Laryngitis
- Pharyngitis

Management

General

- Lose weight and avoid smoking, coffee and chocolates
- Avoid tight garments and stooping
- Avoid sleeping before 2 hours post prandial

Medication

- Control acid secretion with proton receptor antagonists (e.g. ranitidine), proton pump inhibitors (e.g. omeprazol), Dose:
- Minimize effects of reflux (give alginic acids e.g. gaviscon), Dose:
- Antacids (e.g. magnesium hydroxide), Dose:
- Prokinetic agents (e.g. metoclopramide), Dose:

Surgical treatment

- Nissen fundoplication is the standard surgical treatment
- Vagotomy as an obsolete treatment

5.1.4. Esophageal Cancer

Definition: It is a malignant tumour of the oesophagus, which may be squamous cell carcinoma or adenocarcinoma.

Causes

- Commonly occurs in men over 50 years old
- Smoking
- Alcohol consumption
- Risk factors include male gender, obesity and smoking

Symptoms

- Regurgitation
- Chest pain unrelated to eating
- Difficulty swallowing solids or liquids
- Heartburn
- Vomiting blood
- Weight loss

Investigations

- Barium swallow
- Chest MRI or thoracic CT to determine stage of the disease
- Endoscopic ultrasound to determine stage of the disease
- Esophagogastroduodenoscopy and biopsy
- PET (positron emission tomography) scan
- Stool testing may show blood

Management

- Surgery is the treatment of choice
 - Minimally invasive oesophagectomy
- Chemotherapy, radiation or combination of the two
- Endoscopic dilatation of oesophagus
- Photodynamic therapy
- Palliative care
- Ensure enteral feeding and parental treatment support
- Psychological support both to patient and family

Complications

- Difficulty swallowing
- Severe weight loss from not eating enough
- Metastasis of tumour to other areas

5.1.5. Esophageal Spasm

Definition: Diffuse oesophageal spasms are uncoordinated contractions of oesophagus resulting from motility disorders.

Causes

- Not known
- Predisposing factors include: very cold or hot beverages

Signs and symptoms

- Dysphagia
- Regurgitation
- Substernal midline chest pain
- Odynophagia

Diagnosis

- Clinical
- Investigations:
 - Barium swallow (typical corkscrew oesophagus) x-rays
 - Oesophageal radionuclide transit test (oscillatory or non clearance pattern)

Management

Medical

- Botulium toxins
- Long acting nitrites
- Benzodiazepines
- Psychotropic drugs
- Pneumatic dilatation
- Calcium channel blockers

Surgery

- Considered if medical treatment has failed
- Long oesophageal myotomy

5.1.6. Perforation of oesophagus

Definition: It is a hole through which the contents of oesophagus can pass into the mediasternum, the surrounding area in the chest.

Causes

- Injury during a medical procedure
- Tumour
- Gastric reflux with ulceration
- Previous surgery on the oesophagus
- Swallowing a foreign object or caustic chemicals
- Trauma or injury to the chest and oesophagus
- Violent vomiting

Symptoms and signs

- Pain
- Difficulty swallowing
- Chest pain
- Difficulty breathing
- Tachycardia
- Fever

- Tachypnoea
- Nasal voice (cervical injury)
- Haematemesis (thoracoabdominal segment injury)
- Supraclavicular swelling and crepitus (subcutaneous emphysema)
- Neck pain or stiffness (on perforation of oesophagus)
- Respiratory distress (thoracic injuries)

Investigations

- Chest x-ray may reveal air in the soft tissues of the chest, fluids leaked from oesophagus to the space surrounding lungs or lung collapse
- A chest CT scan may show an abscess in the chest or oesophageal cancer
- Endoscopy (incomplete intramural perforations/ Mallory-Weiss Syndrome)

Complications

- Permanent damage to oesophagus (narrowing or stricture)
- Abscess formation in and around oesophagus
- Infection in and around the lung

Management

Medical

- Administering fluids
- IV antibiotics to prevent or treat infections
- Draining fluids collected around the lung with a chest tube
- Mediasternotomy to remove fluids collected in the mediasternum

Surgery: To repair perforation in the middle or bottom portions of oesophagus

5.1.7. Hiatus Hernia

Definition: It is the protrusion of the upper part of the stomach into the thorax through a tear or weakness in the diaphragm.

Causes / Risk factors

- Heavy lifting or bending over
- Frequent oral hard coffee, hard sneezing
- Pregnancy and delivery
- Violent vomiting
- Straining with constipation
- Obesity
- Hereditary smoking

Signs and symptoms

- May be asymptomatic
- Dull pains in the chest
- Shortness of breath
- Heart palpitations

Diagnosis

- Clinical
- Investigations
 - Upper GI series,
 - Endoscopy
 - High resolution manometry

Management

General

- Treatment may not be required
- Bed elevation after meals
- Stress reduction techniques
- Weight loss if overweight

Medical

- Proton pump inhibitors
- H₂ receptor blockers

Surgical

- Nissens fundoplication

Complications

- Oesophageal cancer
- Gasbloat Syndrome
- Dysphagia
- Dumping Syndrome
- Achalasia

5.2. Acute Abdomen

Definition: Acute abdomen is used to describe a group of acute life-threatening intra abdominal conditions (including pelvis) that require emergency hospital admission and often emergency surgical intervention. Early recognition, adequate resuscitation and prompt treatment are necessary for recovery of these patients from potentially fatal conditions.

Causes

Inflammatory

- Secondary bacterial peritonitis: localized, generalized
- Primary bacterial peritonitis: generalized
- Tertiary peritonitis: generalized, very poor prognosis

Traumatic

- Injury to solid organs: acute intra abdominal bleeding
- Peritonitis secondary to intestinal injury

Obstructive

- Acute intestinal obstruction (small bowel)
- Chronic intestinal obstruction (colonic)

Vascular

- Mesenteric infarction
- Strangulated external/internal hernia
- Volvulus (small or large intestine)

Signs and symptoms

- Pain
- Appetite: anorexia, nausea, vomiting, dysphasia, weight loss
- Bowels habits: bloating, diarrhea, constipation, flatulence
- Tenderness
- Rigidity

- Masses
- Altered bowel sounds
- Evidence of malnutrition
- Bleeding
- Jaundice

Abdominal pain from any cause is mediated by either visceral or somatic afferent nerves, and several factors can modify expression of pain:

- Age extremes
- Vascular compromise (pain out of proportion)
- Pregnancy
- CNS pathology
- Neutropenia

Diagnosis

- Clinical presentation
- Investigations
 - Haemogramme
 - Renal function tests and electrolytes
 - Amylase
 - Chest x-ray and abdominal films (erect/supine)
 - Blood culture for high fever and pyrexia
 - Ultrasound and CT-scan
 - DPL
 - Mesenteric angiography
 - Laparoscopy/laparotomy

Management

- Acute abdomen requires immediate treatment
 - Start large bore IV with either saline or lactated ringer's solution
 - IV pain medication
 - Nasogastric tube if vomiting or concerned about obstruction
 - Foley catheter to follow hydration status and to obtain urinalysis
 - Antibiotic administration if suspicious of inflammation or perforation
 - Definitive therapy or procedure will vary with diagnosis
 - Avoid oral intake
 - Oxygen administration if necessary
 - Remember to reassess patient on a regular basis

5.3. Peritonitis

Definition: Peritonitis is inflammation (irritation) of the peritoneum.

Causes

- Bacterial peritonitis
 - Secondary bacterial peritonitis (from GIT): common
 - Primary bacterial peritonitis (streptococcal): rare
 - Tertiary bacterial peritonitis (ICU patients): uncommon
- Chemicals
 - HCL (early Perforated PUD)
 - Extravasation of urine (bladder rupture)
 - Bile (leak post cholecystectomy)
 - Amylase (pancreatitis)

SPONTANEOUS BACTERIAL PERITONITIS

- Occurs in immunocompromised patients
- Cirrhosis, Wilson's Disease, chronic active hepatitis
- Chronic peritoneal dialysis
- Nephrotic Syndrome
- Usually Gram – negative organisms
- High risk of septic shock and Multi-organ Dysfunction Syndrome
- Poor prognosis

Signs and symptoms

- Systemic features: illness, toxicity, pyrexia, tachycardia, rigors (bacteraemia/septicemia)
- Dehydration
- Local symptoms: pain (localized or generalized) severe, constant, aggravated by movement
- Local signs
- Loss of normal abdominal movement on respiration
- Tenderness, guarding, rigidity, rebound tenderness
- Silent abdomen
- Digital rectal examination may elicit pelvic tenderness, boggy swelling, and cervical tenderness in females

Management

Secondary bacterial peritonitis

- Immediate treatment: (*see treatment of acute abdomen*); ensure large quantities of IV fluids administration and electrolyte replacement accordingly
- Control of urinary output
- Antibiotherapy:
 - If upper gastrointestinal pathology suspected, gram negative aerobe cover (IV ciprofloxacin, cefotaxime, ceftriaxone, imipenem)
 - If lower gastrointestinal pathology suspected, gram negative anaerobe cover (metronidazole)
- Surgical treatment:
 - Lavage of abdominal cavity with 8 to 10 liters of normal saline
 - Treat the cause

Primary bacterial peritonitis

- Haematogenous spread of gram-positive organisms (S. pneumonia) to peritoneal cavity
- Occurs in children and adult females
- Treatment :antibiotics+/-laparotomy to drain pus
- Prognosis is good

Complications

- Septic shock
- Hypovolemic shock
- Multiple organ failure

5.4. Intestinal Obstruction

Definition: It is the inability to pass bowel contents distally (partial or complete). Classified into dynamic (mechanical) and adynamic (paralytic ileus).

Causes

- Extramural
- Adhesions, bands
- Hernias: internal and external
- Compression by Tumors
- Intramural
- Inflammatory disease: Crohn's disease
- Tumors: carcinomas, lymphomas, etc.
- Strictures
- Intraluminal
- Faecal impaction
- Swallowed foreign bodies
- Bezoars
- Gallstone

Signs and symptoms

Cardinal symptoms of intestinal obstructions

- Pain
 - Vomiting
 - Distension
 - Absolute constipation
- Signs of dehydration: a dry tongue: sunken eyes and dry inelastic skin may be noted
 - Patient may be rolling about with colic
 - Pulse usually elevated
 - Temperature is usually normal, a raised temperature and a very rapid pulse indicative of strangulation
 - Per abdomen, distension and visible peristalsis may be observed
 - Vital to carefully search for presence of a strangulated external hernia and presence of an abdominal scar
 - Tenderness
 - A mass may be felt (for example in intussusceptions or cancer of the bowel)
 - The bowel sounds are usually accentuated and tinkling (i.e. metallic)

- Rectal examination
- May reveal an obstructing mass in the pouch of Douglas
- Feel apex of an intussusceptions
- Faecal impaction or an empty rectum (in case of sigmoid volvulus)

The rule that constipation is present in intestinal obstruction does not apply to Richter's Hernia, vascular occlusion and intestinal obstruction associated with pelvic abscess.

Investigations

- Abdominal series with chest x-ray
- CBC: >20,000 indicates bowel gangrene, abscess, peritonitis
>40,000 possible nonocclusive mesenteric ischemia
- Electrolytes and renal function tests
- Urinalysis
- Lactate (mesenteric ischemia)
- Barium enema: can determine cause and site of LBO
- Sigmoidoscopy:
 - Identification of friable mucosa
 - Intraluminal lesions
 - Dead bowel
- Diagnostic and therapeutic for sigmoid volvulus
- Contrast enhanced CT: delineate partial from complete obstruction

Management

- Fluid and electrolyte replacement therapy
- Decompression of the bowel
- Well-timed surgical intervention
- Avoid oral intake
- NG tube for drainage
- Parenteral nutrition through the central line
- Fluid and Electrolytes Replacement Therapy
- Adequate fluid, electrolytes, proteins, and whole blood should be given to stabilize the Blood Pressure and pulse as well as to restore warmth, skin colour, turgor, and adequate venous filling
- The urinary output and specific gravity should be followed as indicators of extracellular fluid adequacy
- The amount and type of replacement will vary and should depend on the patient's condition as measured by criteria such as serum chemistry studies, haematocrit, vital signs, and clinical response to fluid therapy

- Decompression of the bowel
 - Distension may be relieved by intestinal intubation or surgical decompression.
- Operative treatment
 - Proper timing of the operation for intestinal obstruction is essential. Surgery is the most important step, and in case of strangulation or vascular occlusion it is the only effective treatment. Surgical procedures for the relief of intestinal obstruction may be divided into five categories.
- Surgical procedures
 - Relief of intestinal obstruction may be divided into five categories
 - Procedures not requiring opening the bowel- lysis of adhesions, manipulation-reduction of intussusceptions, reduction of obstructed hernia.
 - Enterotomy - for removal of obturation obstruction- gallstones, bezoars.
 - Resection of obstructing lesion or strangulated bowel with primary anastomosis.
 - By-pass: anastomosis around an obstruction.
 - Formation of a cutaneous stoma proximal to the obstruction- catheter enterostomy, caecostomy.

Summary of treatment

- IV fluid replacement
- Bowel decompression via nasogastric tube
- Broad spectrum antibiotics preoperatively for mechanical obstructions
- Adynamic ileus patients: conservative management - IV fluids, NG tube, bowel rest, pain management

5.4.1. Appendicitis

Definition: It is an inflammation of the appendix.

Causes/Predisposing factors

- No clear cause of appendicitis
- Obstruction of appendiceal lumen
- Inflammation of appendiceal lymphoid tissue (about 60%). This inflammation can be
- Gastroenteritis
- Advanced colonic disease such as Crohn's Disease.

Signs and symptoms

- Peri-umbilical pain shifting to right iliac fossa
- Anorexia
- Abdominal pain
- Nausea with or without vomiting
- Low grade fever
- Mac Burney tenderness
- Rebound tenderness
- Dunphy (increase pain with cough)
- Rovsing (lower left quadrant palpation inducing right lower quadrant pain)
- Obturator (pain on internal rotation of the right hip)
- Iliac psoas (pain on extension of the right hip)

Investigations

- FBC- leucocytosis and left shift
- A WBC greater than 20000 suggests a perforation
- Urinalysis often reveals minimal white cells, red cells and bacteria
- β HCG must be checked in female patients
- Plain films- a fecalith is present in less than 15% of cases, free air from perforation is seen in 1% of cases
- Ultra sound; most effective in young females of child bearing age in the evaluation of adnexal diseases which is high on differentials. (Sensitivity 75-90%)
- CT scan (sensitivity ranging from 96-100%)
- Radionuclide (sensitivity and specificity >90%)

Management

The goal of surgical approach to appendicitis is simple-early diagnosis with resection of an acutely inflamed appendix prior to perforation, with a minimum of negative appendectomies.

Medical treatment

- *Augmentin* 1gm x 3/ day/ 5 days if uncomplicated appendicitis

Alternative

- *Ceftriaxone*/2g 24 hourly for 5-7 days (adults), or *Cefotaxime* 1g/ every 8 hours + *Metronidazole* 500mg/every 8 hours IV

Surgical treatment

- Open or laparoscopic appendectomy and antibioprohylaxis ceftriaxone 2 gm single dose + metronidazole 500mg single

5.4.2. Appendiceal Mass and Abscess

Definition: Appendiceal mass is a palpable conglomeration of inflamed tissue, including the appendix and adjacent viscera.

Causes/Aetiology

- Idiopathic
- An obstruction (food waste or fecal stone)
- An infection

Signs and symptoms

- Aching pain that begins around your navel and often shifts to your lower right abdomen
- Pain that becomes sharper over several hours
- Tenderness that occurs when you apply pressure to your lower right abdomen
- Sharp pain in your lower right abdomen that occurs when the area is pressed on and then the pressure is quickly released (rebound tenderness)
- Pain that worsens if you cough, walk or make other jarring movements
- Nausea
- Vomiting

- Loss of appetite
- Low-grade fever
- Constipation
- Inability to pass gas
- Abdominal swelling

Diagnosis

- Clinical
- Investigation
 - CT scan of the abdomen and the appendix

The major complications

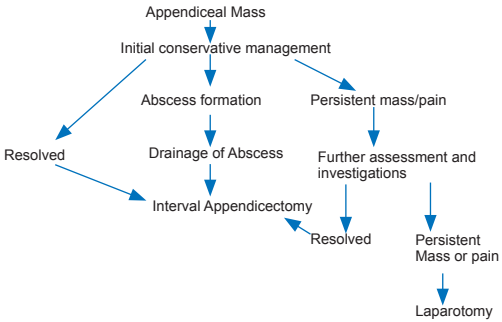
- Peritonitis
- Surgical wound infections
- Intra-abdominal abscess
- Fistulas
- Small bowel obstruction (adhesions)
- Paralytic ileus
- Infertility
- Sepsis

Management

- Conservative treatment with antibiotics (Ochsner Method)
- Percutaneous drainage of abscess and concomitant IV antibiotics
- Appendectomy is done later, 6 weeks to 3 months

Algorithm for management of appendiceal mass

Figure 1. Algorithm for management of appendiceal mass



Annals of African Medicine, Vol.7 No.4 2008: 200 - 204

5.4.3. Gall Stones

Definition: Gall stones are solid particles that form from bile in the gallbladder. They are of two types namely (1) cholesterol stones (20%) and (2) pigment stones yellow stones (80%).

Causes/Risk factors

- Too much cholesterol in the bile
- Excess bilirubin in the bile
- People with liver disease or blood disease
- Poor muscle tone
- Risk factors include, female gender, overweight, losing a lot of weight quickly on a “crash” or starvation diet, certain medication e.g. birth control pills, cholesterol lowering drugs

Signs and symptoms

- Usually asymptomatic (8-15%)
- Biliary colic, nausea and vomiting, approximately 70% will have 1 or more recurrent episodes of pain within a year of onset of symptoms.

Investigations

- Ultrasound (95-99% sensitive)
- MRCP (92% sensitive)
- CT scan (60% sensitive)
- X-ray (15% sensitive)

Complications

- Severe abdominal pain
- Pancreatitis
- Gallbladder disease
- Infection (Cholecystitis)

Management

- Symptomatic treatment
- Intake of only clear liquids to give the gallbladder a rest
- Avoid fatty or greasy meals
- Take acetaminophen (Tylenol, etc.) for pain
- Laparoscopic cholecystectomy should be performed for patients with symptoms

5.4.4. Acute Cholecystitis

Definition: Prolonged or recurrent cystic duct blockage by a gall stone or biliary stasis that can progress to total obstruction.

Cause

- 90-95% of cases are associated with cholelithiasis.

Symptoms

- Right upper quadrant pain with possible radiation to the right shoulder or back
- Nausea, vomiting
- Fever

Investigations

- Ultra sound (non invasive)
- HIDA is the most sensitive test (Technetium 99m pertechnetate immunodiacetic acid scan)

Management

Medical

- IV fluids
- *Ampicilline* IV 1 g tid for 7days + *Gentamycin* IV 160 mg OD for 5days

Alternative

- *Ceftriaxone* IV 1gm bid for 7days
- *Pethidine* 100mg IV 3-4 times/ per day for analgesia

Surgical

- Cholecystectomy is a definitive treatment, if performed within 2-3 days of illness it is better than delayed cholecystectomy that is performed 6-10 weeks after initial medical treatment
- Laparoscopic cholecystectomy is the procedure of choice

5.4.5. Jaundice

Definition: Jaundice is the yellowing of the skin and sclera from accumulation of the pigment bilirubin in the blood and tissue. The bilirubin level has to exceed 35-40 μ mol/l before jaundice is clinically apparent. The three forms of jaundice are: Prehepatic (*Hemolytic*), Hepatic (*hepatocellular*) and Posthepatic (*obstructive/surgical jaundice*).

Surgical (Obstructive) Jaundice

- Post hepatic conjugated bilirubinemia occurs from anything that blocks release of conjugated bilirubin from the hepatocytes or prevents its delivery to the duodenum.

Causes

- Choledocholithiasis
- Periampullary carcinomas
- Portal lymphadenopathy
- Sclerosing cholangitis

Signs and symptoms

- Frank Jaundice
- Pruritis
- White stool
- Coca-cola coloured urine

Investigations

- Serum bilirubine
- Liver function test
- Alkaline phosphatase: elevated
- γ -GT: elevated
- Transaminase: normal/elevated
- Lactate dehydrogenase: normal/elevated
- Reticulocytes: normal
- Ultrasound
- CT-scan
- PTC
- ERCP

Management

- Preoperative management: Aims at preventing complications associated with severe cholestasis such as (infections, clotting disorders, renal failure, liver failure, fluids and electrolyte abnormalities)

Surgical

- Surgical obstructive jaundice will always be accompanied by dilatation of the biliary tree
 - Establishing the cause of the jaundice
 - Assessment of the general condition of the patient
 - Staging in patients with tumours
 - Surgical (endoscopic, radiological)
- Post operative sepsis after biliary tract surgery is common and therefore prophylactic antibiotics should be given to lower the incidence
- IV fluids should be administered to prevent hepato-renal syndrome
- The most common disorder of coagulation is prolonged PTT (prolonged prothrombin time) resulting from deficiency of vitamin K dependant factors. Administration of Vit K 10mg IV BID for at least three days before operation is recommended

5.4.6. Gastric Outlet Obstruction

Definition: Gastric outlet obstruction refers to a condition in which the narrow channel leading from the stomach into the Pylorus is physically blocked and as a result food enters the duodenum slowly or is blocked.

Causes

- Benign
 - Peptic ulcer disease
 - Infection, such as tuberculosis and infiltration diseases such as amyloidosis.
 - A rare cause of gastric outlet obstruction is obstruction with gallstone, also termed Bouveret's Syndrome.
- Malignant
 - Tumours of stomach, including adenocarcinoma(and its linitis plastica variant, lymphoma, and gastrointestinal stromal tumour
 - Occasionally, cancers near the pylorus, for example, of pancreas or duodenum.

Signs and symptoms

- Vomiting which typically occurs after meals of undigested food
- Devoid of any bile
- History of peptic ulcers and loss of weight
- Body wasting and dehydration
- Visible peristalsis may be present
- Succussion splash which is a splash-like sound heard over the stomach in the left upper quadrant of the abdomen on shaking the patient, with or without the stethoscope

Investigations

- Esophagogastroduodenoscopy(EGD)
- Abdominal x-ray (Gastric Fluid level)
- Abdominal CT scan

Management

Depends on the cause, and may include either surgery or medical treatment

Pharmacological

- In patients with peptic ulcer disease, the oedema will settle with conservative management with nasogastric suction, replacement of fluids and electrolytes and proton pump inhibitors

Surgical

- Antrectomy (which involves anastomosing the duodenum to the distal stomach) or gastrojejunostomy, indicated in cases of failed medical treatment and recurrent obstruction

6. Disorders of the Colon and Rectum

6.1. Colo-Rectal Cancer

Definition: The occurrence of malignant lesions in mucosa on the colon or rectum.

Causes/predisposing factors

- Prior colorectal carcinoma or adenomatous polyps
- Hereditary Polyposis Syndrome
- Family history of colorectal carcinoma
- Chronic active ulcerative colitis
- Diet (low in indigestible fibre, high in animal fats)
- Decreased fecal bile salts, selenium deficiency

Signs and symptoms

- Anemia, ceacal cancers often present with anemia
- Colicky abdominal pain
- Alteration in bowel habits (constipation or diarrhea)
- Bleeding or passage of mucus per rectum
- Tenesmus (frequent or continuous desire to defecate)

Investigations

- Digital rectal examination and fecal occult blood
- Full Blood Count (anemia)
- Urea and electrolytes (hypokalaemia)
- Liver function test (liver metastasis)
- Sigmoidoscopy (Rigid to 30 cm/flexible to 60 cm)
- Double contrast barium enema (apple core lesion, polyp)
- Carcinoembryonic antigen is often raised in advanced disease

Management

Surgery

- Resection of the tumour with adequate margins to include regional lymphnodes
- Resection possible for liver metastasis if fewer than five are present
- Radiotherapy may be used to shrink rectal cancers pre-operatively or palliate inoperable rectal cancer

- Adjuvant chemotherapy (5-fluorouracil +/- levamisole) to reduce risks of systemic recurrence (DUKE classification C and some DUKE's B) or to palliate liver metastasis
- Supportive management (*see management of oesophageal cancer*)

6.2. Rectal bleeding

Definition: The passage of blood from the anus, the blood volume may be small or large, and may be bright red or dark in colour.

Causes

- In the small intestines
 - MECKEL diverticulum in young adults
 - Intussusceptions in young children (colic abdominal pain, retching, bright red/mucus stool)
 - Interitis, infection, radiation, Crohn's disease
 - Ischemic, severe abdominal pain
- In proximal colon
 - Angiodysplasia, common in elderly carcinoma of the caecum (causes anaemia rather than frank rectal bleeding)
- In the colon
 - Polyps/carcinomas
 - Diverticular disease in the elderly
 - Ulcerative colitis
 - Ischemic colitis in elderly (severe abdominal pain)
- In the rectum
 - Carcinoma (change in bowel habits, associated with mucus, small volumes of blood)
 - Proctitis
 - Solitary rectal ulcer
- In anus
 - Haemorrhoids
 - Fissure in ano
 - Perianal Crohn's disease
 - Carcinomas in anus

Management

- Treat the cause

6.3. Haemorrhoids

Definition: Are masses or clumps (“cushions”) of tissue within the anal canal that contain blood vessels and the surrounding, supporting tissue made up of muscle and elastic fibers.

Causes

- Inadequate intake of fibre
- Chronic straining to have a bowel movement (constipation)
- Pregnancy
- Tumours in the pelvis

Signs and symptoms

- Depends on stage and whether internal or external
 - First-degree hemorrhoids: bleed but do not prolapse.
 - Second-degree hemorrhoids: prolapse and retract on their own (with or without bleeding)
 - Third-degree hemorrhoids: prolapses but must be pushed back in by a finger
 - Fourth-degree hemorrhoids: prolapses and cannot be pushed back in. It also includes hemorrhoids that are thrombosed (containing blood clots) or that pull much of the lining of the rectum through the anus
 - Anal itchiness (pruritus ani)
 - Mass protrusion from the anus that cannot be pushed back inside (incarceration of the hemorrhoid)

Investigations

- Flexible sigmoidoscopy
- Colonoscopy

Complications

- Incarceration of the hemorrhoid
- Thrombosis
- Rectal hemorrhage
- Infection

Management

- Simple: bulk laxatives and high fibre diet
- Bleeding internal haemorrhoids: injection sclerotherapy, Barron's band, cryosurgery
- Prolapsing external haemorrhoids: haemorrhoidectomy
- Stool softeners and increased drinking of liquids can be recommended
- Local anaesthetics e.g. Benzocaine 5% to 20% (Americaine Hemorrhoidal, Lanacane Maximum Strength, Medicone)
- Vasoconstrictors e.g. Ephedrine sulfate 0.1% to 1.25% OR Epinephrine 0.005% to 0.01% **Or**
- Phenylephrine 0.25% (Medicone Suppository, Preparation H, Rectacaine)
- Rectal prolapsis: Abdominal rectopexy (rectum is hitched up on to the sacrum)

Perianal hematoma: evacuation of the clot

Anal fissure:

- *First line treatment:* stool softeners / balking agents, local anaesthetic gels 0.2% GTN (Glyceryl trinitrate) ointment
- *Second line treatment:*
 - Botulinum toxin injection, lateral internal sphincterotomy
 - Examination under anaesthesia and biopsy for atypical/suspicious abnormal fissures

6.4. Perianal Abscess

Definition: Perianal abscess is a collection of pus in the area of the anus and rectum.

Causes/Risk factors

- Blocked gland in the area
- Infection of an anal fissure
- Sexually transmitted infection
- Inflammatory bowel disease (Crohn's disease and ulcerative colitis)
- Anal sex
- Chemotherapy drugs used to treat cancer
- Diabetes
- Use of medication such as prednisone
- Weakened immune system (such as from HIV/AIDS)

Signs and symptoms

- Swelling around the anus
- Constant, throbbing pain
- Pain with bowel movement which may be severe
- Constipation
- Discharge of pus from the rectum
- Fatigue and general malaise
- Fever, night sweats and chills
- Lump or nodule, swollen, red, tender at edge of anus
- Painful, hardened tissue on rectal examination
- In infants, the abscess often appears as a swollen, red, tender lump at the edge of the anus. The infant may be fussy and irritable from discomfort

Investigations

- Proctosigmoidoscopy
- Ultrasound/CT scan/MRI to rule out other diseases

Complications

- Anal fistula
- Body-wide infection (sepsis)
- Continuing pain
- Problem keeps coming back (recurrence)
- Scars

Management

- Incision and drainage of abscess, drained abscesses are usually left open and there are no stitches
- Antibiotics

6.5. Fistula in Ano

Definition: A fistula in ano is a track that develops from the inner lining of the anus through the tissues that surround the anal canal.

Causes

- Previous anorectal abscess
- Anal canal glands situated at the dentate line
- Other causes include trauma, Crohn disease, anal fissures, carcinoma, radiation therapy, actinomycoses, tuberculosis, and chlamydial infections

Signs and symptoms

- Perianal discharge
- Pain
- Swelling
- Bleeding
- Skin excoriation
- External opening
- Digital rectal examination may reveal a fibrous tract or cord beneath the skin
- Lateral or posterior indurations suggests deep post anal or ischiorectal extension
- Recurrent episodes of anorectal sepsis
- An abscess develops easily if the external opening on the perianal skin seals itself

Investigation

- Rectoscopy

Complications

- Incontinence
- Recurrent pain after surgery

Management

- Low: Probing and laying open the track (fistulotomy)
- High: Seton insertion, core removal of the fistula track

6.6. Carcinoma of Anus

Definition: Anal cancer is a disease in which malignant cells form in the tissues of the anus.

Staging process

- CT scan (CAT scan)
- Chest X-ray: An x-ray of the organs and bones inside the chest
- Endo-anal or endorectal ultrasound

Causes/Risk factors

- Human papillomavirus (HPV) infection
- Risk factors include:
 - Being over 50 years old, being infected with human papilloma virus (HPV)
 - Having many sexual partners
 - Having receptive anal intercourse (anal sex)
 - Frequent anal redness, swelling, and soreness
 - Having anal fistula (abnormal openings)
 - Smoking cigarettes

Signs and Symptoms

- Bleeding from the anus or rectum
- Pain or pressure in the area around the anus
- Itching or discharge from the anus
- A lump near the anus
- A change in bowel habits

Investigations

- Anoscopy: An exam of the anus and lower rectum using an anoscope (a short, lighted tube)
- Proctoscopy: An exam of the rectum using a proctoscope (short, lighted tube)
- Endo-anal or endorectal ultrasound
- Biopsy taken for histopathology exams during anoscopy

Management

- Radiation therapy: uses high-energy x-rays or other types of radiation to kill cancer cells
- Chemotherapy: uses drugs to stop the growth of cancer cells

- Surgery
 - Local resection
 - Abdominoperineal resection
- Combined local radiotherapy and chemotherapy: This displaced the traditional abdominoperineal resection

6.7. Acute Pancreatitis

Definition: Pancreatitis is an inflammatory condition of the exocrine pancreas that results from injury to the acinar cells. It may be acute or chronic.

Causes

- Gallstones and alcohol abuse account for 95% of cases of acute pancreatitis
- Idiopathic
- Other causes include congenital structural abnormalities, drugs, viral infections, hypocalcaemia, hypothermia, hyperlipidemia, trauma

Signs and symptoms

- Abdominal pain felt in the upper left side or middle of the abdomen
- Illness, fever, nausea, vomiting and sweating (acute pancreatitis)
- Clay-colored stools, gaseous abdominal fullness, hiccups, jaundice, skin lesions and swollen abdomen
- Abdominal tenderness or mass, low Blood Pressure, rapid heart rate and rapid Respiratory Rate are observed on physical examination

Investigations

- Complete Blood Count
- Increased blood amylase level, increased serum blood lipase level, increased urine amylase level, comprehensive metabolic panel
- Abdominal ultra sound
- Abdominal CT scan
- Abdominal MRI

Management

Most pancreatitis is mild and resolves spontaneously.

- Assess disease severity (Imri / Ranson Criteria or APACHEII system)
- Resuscitate the patient if:
 - Mild/moderate disease: IV fluids, analgesia, monitor progress with pulse Blood Pressure and temperature.
 - Severe pancreatitis: full resuscitation in ICU with invasive monitoring
 - Avoid oral intake
- *Establish the cause:* ultrasound to look for gallstones
- *Further management:* Non proven use for routine nasogastric tube or antibiotics
- Consider vitamin supplement and sedatives, if alcoholism is the cause
- Proven common bile duct stones require urgent ERCP (Endoscopic retrograde cholangiopancreatography)
- Failure to respond to treatment or uncertain diagnosis warrants abdominal CT- Scan
- Suspected or proven infection of necrotic pancreas requires antibiotics and surgical debridement

Complications

- Pancreatic abscess
- Intra-abdominal sepsis
- Necrosis of the transverse column
- Respiratory failure (ARDS) or renal failure (Acute tubular necrosis)
- Pancreatic hemorrhage
- Pancreatic pseudo cyst: may need to be drained internally or externally
- Chronic pancreatitis

6.8. Chronic Pancreatitis

Definition: Chronic pancreatitis is inflammation of the pancreas that does not heal or improve, gets worse over time, and leads to permanent damage.

Causes

- Chronic alcohol abuse
- Repeat episodes of acute pancreatitis
- Damage to the portions of the pancreas that make insulin may lead to diabetes
- Risk factors include autoimmune, blockage of the pancreatic duct, cystic fibrosis, high levels of triglycerides in the blood (hypertriglyceridemia), hyperparathyroidism, use of certain medication (especially estrogens, corticosteroids, thiazide diuretics, and azathioprine)

Signs and symptoms

- Intractable abdominal pain
- Evidence of exocrine pancreatic failure (steatorrhea)
- Evidence of diabetes

Management

Medical

- Analgesia
- Exocrine pancreatic enzyme replacement

Surgical

- Drainage of dilated pancreatic duct or excision of the pancreas in some cases
- Splanchicectomy is performed in intractable pain

7. Genito-Urinary Disorders

7.1. Traumatic Disorders

7.1.1. Renal Injuries

Causes

- Blunt trauma (60-90%)
- Penetrating trauma

Signs and symptoms

- Hematuria(>99%)
- Flank tenderness / ecchymosis
- Hemodynamic instability
- Flank pain
- Signs and symptoms of other abdominal injuries are present

Investigations

- FBC
- Renal function tests
- Ultrasonography
- Prothrombine time
- Thromboplastine time
- IVP (visualization or “non-vis”)
- CT scan with contrast

Management

The management is based on classification of renal injuries.

- Grade I to III
 - Manage conservatively with bed rest, antibiotics, serial hematocrits and a repeat CT between 48 and 72 hours
 - Urinary extravasation requires stent
- Grade IV to V
 - Requires surgical exploration, nephrectomy done after confirming a functioning contralateral kidney

7.1.2. Ureter Injury

Causes

- Usually iatrogenic
- Penetrating trauma more common than blunt trauma

Signs and symptoms

- Unilateral
- Asymptomatic, secure ligation of the ureter gives silent atrophy of the kidney
- Tenderness in the loin
- Fever, possible with pyonephrosis due to infection of the obstructed system
- Urinary fistula through the wound
- Abdominal distension following uroperitoneum
- Bilateral
- Ligation of both ureters gives anuria
- No passage of ureteric catheter
- Bilateral hydronephrosis

Investigations

- Non single test is reliable:
 - Pre-operation CT scan with IV contrasts and delayed images can suggest injury
 - IV methylene blue bolus with lasix can be given in operation room

Management

- If recognized immediately repair with stenting
- If late diagnosis: repair but high nephrectomy rate (30%)
 - Techniques for an abdominal ureteral injury repair
 - Spatulate
 - Stent
 - Tension free uretero-ureterostomy
 - Techniques for pelvic ureteral repair
 - Psoas hitch
 - Downward nephropexy
 - Reimplantation in the bladder
- Management of the ureteral contusion by a stent (a bladder can be opened to place the stent under direct vision or endoscopically)

- Delayed diagnosis (less than 5 days) consider repair
- If greater than 5 days, control urinary extravasation with ureteral stent, urinary diversion and urinoma drainage

7.1.3. Bladder Injury

Causes

- Penetrating or blunt trauma
- Pelvic trauma

Signs and symptoms

- No bladder distension
- Gross hematuria
- Difficult or inability to void
- Suprapubic or abdominal pain or tenderness
- Abdominal distension
- Delayed presentation associated with intoxication due to uric acid accumulation

Investigations

- FBC
- Renal function test
- Ultrasonography
- CT scan
- Retrograde cystography
- Intravenous urography

Management

- Indwelling foley catheter (10-14 days), if extraperitoneal ruptures
- Exploration and repair, if intraperitoneal rupture
- Manage associated injuries if any

7.1.4. Urethral Injury

90% of urethral injuries are at the posterior urethra

Causes

- Posterior urethra: Pelvic fractures (most commonly associated with bilateral pubic rami-fractures)
- Anterior urethra: Direct trauma

Signs and symptoms

- Blood at urethral meatus
- High riding prostate (freely mobile) on DRE
- Inability to urinate/palpable full bladder
- Perineal hematoma

Investigation

- Retrograde urethrogram

Management

- Primary endoscopic realignment if posterior urethral injury
- Supra-pubic cystostomy and urethroplasty at 4 weeks to 3 months
- Open anastomotic repair if anterior urethra

Complications

- Impotence
- Incontinence
- Strictures

7.1.5. Testicular Injury

Blunt trauma involves testicular rupture in 50% of cases.

Cause

- Blunt or penetrating trauma

Signs and symptoms

- Scrotal pain
- Ecchymosis
- Hematocele
- Swelling of testis

Investigations

- FBC
- Ultrasonography

Management

- Conservative management with analgesics (paracetamol 1g every 8 hours for 5 days) and scrotal elevation
- Exploration, if tender scrotum/suspicion of testicular rupture
- Orchidectomy, if delayed exploration of a significant testicular injury
- Psychologic support treatment for patient with severe testicular injury

7.2. Non Traumatic Disorders

7.2.1. Urinary Tract Infections (UTI)

Definition: Is a significant bacteriuria of the urinary system (colony count of greater than 100000 organisms per milliliter). It may affect upper urinary tract (pyelonephritis, renal abscess) or lower urinary tract (cystitis, urethritis), or both.

Cause/Risk factors

- Urinary tract obstruction
- Instrumentation (e.g. in dwelling catheter)
- Neurogenic bladder
- Diabetes mellitus
- Vesico-ureteric reflux
- Immunosuppression
- Pregnancy

Signs and symptoms

- Upper UTI
- Fever
- Chills/rigors
- Flank pain
- Malaise
- Anorexia
- Costovertebral angle and abdominal tenderness
- Lower UTI
- Dysuria
- Frequency
- Urgency
- Suprapubic pain
- Hematuria
- Scrotal pain (epididymo-orchitis) or perineal pain (prostatitis)

Investigations

- Upper urinary tract infection
- FBC
- Urinalysis
- Renal function tests
- Electrolytes
- Renal ultrasound
- Intravenous urogram
- CT scan
- Isotope scan
- Lower urinary tract infections
- FBC
- Urinalysis
- Cystoscopy(if hematuria or obstruction)
- Ultrasound,IVU(intravenous urography)

Complications

- Bacteremia and septic shock
- Chronic and xanthogranulomatous pyelonephritis
- Renal and perinephric abscesses

Management

- If Upper UTI, epididymo-orchitis and prostatitis
 - Treat underlying causes (e.g. relieve obstruction)
 - Intravenous appropriate antibiotic therapy. Agents commonly used are gentamycin 160 mg OD /5 days, cefotaxime 1g TDS/ 7 days for adult or 50 to 100mg/kg/day divided in 3 doses in children or ceftriaxone 1-2 gr OD/ 7 days for adult or 50mg/kg/day in one dose

- If Cystitis and uncomplicated lower UTI:
 - Treat underlying causes (e.g. relieve obstruction)
 - Managed with oral antibiotics: amoxicilline 500mg TDS/7 days, nitrofurantoin 100mg, 2 tabs BID/10 days, cephalosporine(cefuroxime 500 mg BID/ 5-10 days)
 - Encourage high fluid intake
 - Drainage either radiologically or surgically, if abscess

- If there is poor response to treatment, consider unusual UTI
 - Tuberculosis (sterile pyuria)
 - Candiduria
 - Schistosomiasis
 - N.gonorrhoea
 - Chlamydia trachomatis

7.2.2. Hematuria

Causes/ risk factors

- Pseudohematuria: menses, dyes (beets, rhodamine B in drinks, candy and juices), hemoglobin (hemolytic anemia), myoglobin (rhabdomyolysis), porphyria, laxatives (phenolphthalein).
- Based on source of bleeding: pre-renal, anticoagulants, coagulation defects, sickle cell disease, leukemia.
- Renal: renal tumours, infections, trauma, ureter, stone, tumour
- Bladder: infections, tumour, stone, Polyps, Urethra: infections, stone, tumour, urethral stricture

Diagnosis

- History: flank pain, irritative or obstructive symptoms, recent UTI, STDs, TB exposure, pelvic irradiation, bleeding diathesis, smoking, drugs (NSAIDs, anticoagulants), diabetes, sickle cell anemia, polycystic kidney disease, urinary tract calculi

- Physical exam
 - Abdominal exam - abdominal masses (including renal or bladder) or tenderness
 - GU exam - DRE for prostate, external genitalia in males

Investigations

- FBC (rule out anemia, leukocytosis)
- Chemistry: electrolytes, creatinine, BUN
- Urinalysis: culture and sensitivity and cytology
- Ultrasound
- CT with contrast
- Cystoscopy
- Intravenous pyelogram (IVP)

Management

- Irrigation with normal saline to remove clots
- Cystoscopy and stop bleeding
- Intravesical instillation of 1% silver nitrate solution
- Intravesical instillation of 1-4% formalin (need general anesthesia)
- Embolization or ligation of iliac arteries
- Partial or total cystectomy

7.3. Testicular and Scrotal Disorders

7.3.1. Testicular Torsion

Definition: Testicular torsion is the twisting of the spermatic cord, which cuts off the blood supply to the testicles and surrounding structures within the scrotum. It is the most common cause of acute scrotal pain in boys.

Causes

- Inadequate connective tissue within the scrotum
- Trauma to the scrotum, particularly if significant swelling occurs
- Strenuous exercise
- The condition is more common during infancy (first year of life) and at the beginning of adolescence (puberty)

Signs and symptoms

- Acute scrotal pain
- Swelling of the scrotum or testis
- High transverse lying testis
- Nausea or vomiting
- Light-headedness
- Testicle lump
- Blood in the semen

Investigations

- Scrotal ultrasound with colour Doppler
- Nuclear scintigraphy

Complications

- Testicular atrophy (shrink) and need to be surgically removed
- Severe infection of the testicle and scrotum possible if the blood flow is restricted for a prolonged period

Management

- Take immediately to surgery within 6 hours to save testis
- Reduction and orchidopexy if testis still viable
- Orchiectomy if testis are infarcted
- Contralateral orchidopexy

7.3.2. Fournier Gangrene

Definition: It is a necrotizing fasciitis of the male genitalia and perineum.

Causes/risk factors

- Urethral stricture
- Perirectal abscesses
- Poor perineal hygiene
- Diabetes
- HIV
- Immunocompromised states

Signs and symptoms

- Fever
- Perineal and scrotal pain
- Cellulitis
- Necrosis of the scrotum
- Flanking skin
- Crepitus

Investigations

- FBC
- HIV test
- Glycemia
- Pus culture for sensitivity

Management

- Prompt debridement of nonviable tissues
- Broad spectrum antibiotics (Ceftriaxone 1-2gr BID or cefotaxime 1-2gr TDS + metronidazole 500 mg TDS 5-10 days)
- Colostomy, if there is damage to the external anal sphincter
- Glucose control and adequate nutrition are necessary to facilitate wound healing

7.3.3. Testicular Cancer

Definition: Testicular cancer is the malignant lesion of the testis.

Causes/risk factors

- Cryptorchidism
- Risk is unaffected by orchidopexy
- Higher incidence in the whites

Signs and symptoms

- Painless swelling of the testis
- Vague testicular discomfort
- Rarely, evidence of metastatic disease or gynecomastia
- Hard irregular non tender testicular mass

Investigations

- Blood for tumor markers, AFP and HCG
- Scrotal ultrasound
- Chest x-ray to assess lungs and mediastinum
- CT scan of the chest and abdomen to detect lymphnodes
- Laparoscopy (retroperitonoscopy)

Management

- Orchiectomy (groin incision) and histological diagnosis
- Further treatments depend on histology and staging
- If seminoma
 - Stage I and II: radiotherapy to the abdominal nodes
 - Stage III: chemotherapy(bleomycin, cisplatin and etoposide)
- If non seminoma germ cell
 - Stage I: RPLND
 - stage II: Chemotherapy + RPLND
 - stage III: Chemotherapy

7.3.4. Hydrocele

Definition: Hydrocele is the collection of fluid within tunica vaginalis.

Causes

- Congenital
- Idiopathic
- Secondary (intrascrotal pathology such as tumour, torsion, trauma or infection)

Signs and symptoms

- Fluctuant
- Trans-illuminate
- Swelling
- Non tender

Investigations

- Ultrasound
- Urinalysis
- FBC

Management

- Surgery
- Lord's procedure in adults
- Herniotomy in children

7.3.5. Undescended Testis

Definition: Interruption of the normal descent of the testis into the scrotum

Causes/risk factors

- Prematurity

Signs and symptoms

- Absence of testis in the scrotum
- Palpable mass in the inguinal canal
- Difficult or impossible to palpate the testis (abdominal testis or congenital absence of the testis)

Investigations

- Hormonal dosage (chorionic gonadotropin levels)
- Spermogram
- Ultrasound
- Laparoscopy

Management

- Unilateral undescended testis: surgical repositioning (orchidopexy) before two years of age
- Bilateral undescended testis
- Chorionic gonadotropine
- Operative correction (failure of descent after one month of therapy)
- Protheses (testicular agenesis)

7.3.6. Varicocele

Definition: Is dilatation and tortuous veins within the pampiniform plexus of scrotal veins.

Cause and risk factors

- Valvular incompetency or absence of the valves at the termination of the left testicular vein
- Venous occlusion by renal or retroperitoneal tumors

Signs and symptoms

- Common on the left side
- Dragging-like or aching pain within the scrotum
- Feeling of heaviness in the testicle
- Atrophy of the testicle
- Visible or palpable enlarged vein
- Likened to feeling a bag of worms

Investigation

- Color Doppler ultrasonography

Management

- Medical therapy: no effective medical treatment have been identified
- Embolization (first choice treatment)
- Gonadal vein ligation (inguinal canal or low tie/ retro peritoneum or high tie)

7.4. Disorders of the Penis

7.4.1. Priapism

Definition: Is a persistent erection for greater than 4 hours unrelated to sexual stimulation. It can be low flow (ischemic) or high flow (traumatic).

Causes/risk factors

- Most priapiasms are idiopathic
- Sickle cell disease
- Medication (e.g. antidepressant anti psychosis chlorpromazine)
- Pelvic tumors
- Malignancies (leukemia)
- Spine cord injury
- Penile injections for erectile dysfunctions
- Cocaine abuse
- Total parenteral nutrition

Signs and symptoms

- Persistent erection
- Tenderness of the penis
- Cavernous bodies rigid while the glans will be flaccid

Investigations

- Blood analysis (gases, cell count and morphology)
- Abdominal ultrasound
- Color Doppler ultrasound
- Angiography

Management

- Low flow priapism: medical management if Priapism results from sickle cell disease and leukemia
 - hydration
 - oxygenation
 - alkalinisation
 - Transfusions or exchange transfusions should be considered
 - Irrigation of corpora cavernosa (phenylephedrine 5 mg in 500 ml of Normal saline) when diagnosed before 36 hours

- Distal shunt (winter shunt)
- Proximal shunt if distal shunt fails
- High flow priapism
 - Selective embolization
 - Fistula surgical ligation if embolization fails

7.4.2. Paraphimosis

Definition: Is the retraction of foreskin behind the corona of the glans penis reducing a tonic effect.

Causes

- Trauma
- Latrogenic

Signs and symptoms

- Oedema of the fore skin and glans penis
- Pain
- Fore skin ulceration

Management

- Reduction under anaesthesia
- Operation (circumcision)

7.4.3. Phymosis

Definition: Is tightness of the fore skin of such a degree as to prevent retraction.

Causes

- Congenital
- Secondary to infection

Signs and symptoms

- Ballooning of the fore skin micturation
- Failure of retraction
- Small contracted orifice

Management

- Circumcision

7.4.4. Hypospadias

Definition: A condition where the urethral orifice opens in abnormal position on the ventral surface of the penis or scrotum.

Causes /risk factors

- Use of maternal estrogen or progesterone during pregnancy
- Hereditary

Signs and symptoms

- Difficulty directing the urinary stream and stream spraying
- Chordee
- Males with this condition often have a downward curve (ventral curvature or chordee) of the penis during an erection
- Abnormal spraying of urine
- Having to sit down to urinate
- Malformed foreskin that makes the penis look “hooded”

Investigations

- A physical examination can diagnose this condition
- A buccal smear and karyotyping
- Urethroscopy
- cystoscopy
- Excretory urography

Complications

- Difficulty with toilet training
- Problems with sexual intercourse in adulthood
- Urethral strictures and fistulas may form throughout the boy's life

Management

- Infants with hypospadias should not be circumcised
- For a Minor degree of hypospadias (e.g. glandular hypospadias) require no treatment

Surgical management

- During the surgery, the penis is straightened and the hypospadias is corrected using tissue grafts from the foreskin. The repair may require multiple surgeries

- Relief of the chordee
- Urethral reconstruction
- In some cases, more surgery is needed to correct fistulas or a return of the abnormal penis curve

Recommendations

- Surgery is usually done before the child starts school
- Surgery can be done as young as 4 months old, better before the child is 18 months old

7.4.5. Carcinoma of the Penis

The majority of penis malignancies are squamous cell carcinomas.

Causes and risk factors

- Oriental origin
- Age
- Human papillomavirus (HPV) and balanitis xerotica obliterans infection
- Smoking
- Smegma and phimosis
- Treatment of psoriasis with UV light
- AIDS
- Poor hygiene related to non circumcision and STDs

Signs and symptoms

- Redness
- Irritation
- Sore on the penis
- Indurations or erythema
- Ulceration
- Small nodule, or an exophytic growth

Diagnosis

- Biopsy for histopathology tests

Management

Primary lesion

- Circumcision: lesion localized to the prepuce
- Radiotherapy: glans alone affected and tumor \leq 1cm

- Partial amputation: shaft of the penis is involved
- Total amputation: extensive involvement of the shaft
- Antibiotics for 6 weeks before evaluating the inguinal nodes

Inguinal lymph nodes

- Careful follow up if impalpable nodes
- Radical dissection if palpable mobile nodes persisting 3 months after initial treatment
- Fixed inguinal lymph node: chemotherapy with bleomycine, cisplatin and methotrexate

7.4.6. Impotence

Definition: Persistent inability to obtain and sustain an erection sufficient for sexual intercourse.

Causes

- Psychological
- Neurological causes (spinal cord lesions, myelodysplasia, multiple sclerosis, tabes dorsalis, peripheral neuropathies)
- Diabetes mellitus
- Endocrine (hypogonadotropic hypogonadism Klinefelter's Syndrome or surgical orchidectomy)
- Low testosterone levels (prolactin producing tumors)
- Vascular (atherosclerosis)
- Trauma (perineal, posterior urethra, pelvic fracture leading to arterial injury, uraemic chronic dialysis)
- Iatrogenic (radical prostatectomy, cystoprostatectomy, neurological surgical procedures, transurethral endoscopic procedures, pelvic irradiation procedures)
- Medication (centrally acting agents, anticholinergic agents (antidepressant), anti-androgenic agents (digoxin), hyperprolactinemic agent (cimetidine), sympatholytic agent (methyl dopa)

Diagnosis

- Detailed history
- Physical examination
- Length, plaques and deformity of the corporal bodies of penis
- Presence or absence of testis
- Size and consistency of the penis

- Gynecomastia (endrogene deficiency)
- Neurological assessment
- Sensory function of the penis and perineal skin
- Bulbo cavernosus reflexe to evaluate the sacral reflexes

Investigations

- Nocturnal penile tumescence (change in penis size during sleep)
- Dynamic infusion cavernosometry and cavernosonography (to assess venous/corporal leak)

Management

Psychological

- Treated by trained psychotherapist or sex therapist

Medical therapy

- Sildenafil(viagra), tadalafil (cialis)
- Apomorphine (uprima)
- Intracorporal administration of vasoactive substances (papaverine hydrochloride alone or associated with vasodilator like phentolamine, or prostaglandin E1)
- Androgen replacement therapy with testosterone
- Vacuum suction devices

Surgical therapy

- Penile prostheses
- Vascular surgical techniques like micro surgical anastomosis of inferior epigastric artery to the dorsal penile artery

7.5. Disorders of the Urethra

7.5.1. Urethra Meatal Stenosis

Definition: Is a narrowing of the opening of the urethra, the tube through which urine leaves the body.

Causes

- Congenital
- Failure of normal canalization
- Treat at time of endoscopy with dilatation, internal urethrotomy
- Trauma
- Instrumentation (most common, at fossa navicularis)
- External trauma
- Urethral trauma with stricture formation
- Infection
- Common with gonorrhoea in the past (not common now)
- Long-term indwelling catheter
- Balanitis xerotica obliterans - causes meatal stenosis

Signs and symptoms

- Decreased force/amount of urinary stream
- Spraying
- Double stream
- Post-void dribbling
- Related infections: recurrent UTI, secondary prostatitis / epididymitis

Investigations

- Dynamic: flow rates < 10 mL/s (normal = 20 mL/s)
- urine culture
- urethrogram, VCUG (voiding cysto urethrography) will demonstrate location
- urethroscopy

Management

- Urethral dilatation
- Temporarily increases lumen size by breaking up scar tissue
- Healing will reform scar tissue and recreate stricture
- Not usually curative

- Internal urethrotomy (IU)
- Endoscopically incise stricture without skin incision
 - Only single and short (< 1 cm), bulbar urethra strictures respond
 - Cure rate 50-80% with single treatment, < 50% with repeated courses
- Open surgical reconstruction
 - Complete stricture excision for all, then (dependent on location and size of stricture):
 - Membranous urethra – end-to-end anastomosis
 - Bulbar urethra < 2 cm – end-to-end anastomosis
 - Bulbar urethra > 2 cm or penile urethra – 1) vascularized flap of local genital skin or 2) free graft (penile shaft skin or buccal mucosa) – preferred

7.6. Disorders of the Prostate

7.6.1. Benign Prostatic Hyperplasia (BPH)

Definition: An increase in size of the inner zone of the prostate gland. It is a disease common in elderly men. BPH never progresses to carcinoma.

Causes

- Not known
- Predisposing factors are age, normally functioning testes, race, geographical location, sexual behavior, diet, alcohol, tobacco (no evidence that they play a part).

Signs and symptoms

- Nocturia
- Urgency and frequency
- Weak stream and hesitancy
- Acute urinary retention
- Urinary tract infections
- Renal failure
- Urinary stones
- Haematuria

Management

- Medical therapy (Alpha Blockers and androgen suppression)
- Minimally invasive surgery (Trans urethral microwave thermotherapy, transurethral needle ablation)
- Surgery (TURP (trans-urethral resection prostate), open surgery)

7.6.2. Prostatic Cancer

Adenocarcinoma is the most common type (greater than 90%). It primarily develops in the peripheral portion of the prostate gland.

Causes/Risk factors

- Age
- Family history

Investigations

- PSA is used in conjunction with DRE to help provide early detection of the disease
- PSA is also used to detect biochemical disease recurrence following treatment
- Patient with an elevated PSA and/or abnormal DRE are recommended to undergo TRUS guided biopsy
- Metastatic work up should be performed in selected patient based on clinical picture (work up usually comprises bone scan and CT against MRI)

Management

- Brachytherapy, external beam radiation therapy or radical retropubic prostatectomy
- At the time of prostatectomy, a pelvic lymphadenectomy is performed first.
- Systemic therapy (androgen deprivation therapy and hormonal therapy) in patients with significant comorbidities and/or more extensive diseases.

7.7. Disorders of the Urinary Bladder

7.7.1. Bladder Calculi/stones

Definition: Bladder calculi/stones are hard buildups of minerals that form in the urinary bladder.

Causes

- Calculi from the kidney
- Bladder outflow obstruction
- Presence of foreign bodies (e.g. urethral catheter)
- Neuropathic bladders
- Bladder diverticulum
- Enlarged prostate
- Urinary tract infection

Signs and symptoms

- Abdominal pain, pressure
- Pain, discomfort in the penis
- Dysuria with frequent urge to urinate
- Abnormally colored or dark-colored urine
- Frequency
- Hematuria
- Nocturia
- Hesitancy
- Weak stream
- Sudden cessation of flow with pain in the perineum and tip of the penis
- Urinary incontinence may also be associated with bladder stones
- Rectal examination may reveal an enlarged prostate

Investigations

- Urinalysis may show blood in the urine, crystals, or an infection
- Urinary culture (clean catch) may reveal infection
- IVU
- Ultrasound
- Bladder or pelvic x-ray may show stones
- Cystoscopy can reveal a stone in the bladder

Complications

- Acute bilateral obstructive uropathy
- Bladder cancer in severe, long-term cases
- Chronic bladder dysfunction (incontinence or urinary retention)
- Obstruction of the urethra
- Recurrence of stones
- Reflux nephropathy
- Urinary tract infection

Management

- Drinking 6 - 8 glasses of water or more per day to increase urinary output may help the stones pass
- Remove stones that do not pass on their own using a cystoscope (a small tube that passes through the urethra to the bladder)
- Treated causes of bladder stones e.g. benign prostatic hyperplasia, bladder outlet obstruction
- Transurethral resection of the prostate (TURP) with stone removal
- Medication is rarely used to dissolve the stones
- Removal of the stones (endoscopically / open surgery) cystolithotomy for very large stones

7.7.2. Bladder Cancer

Definition: Bladder cancer is a cancer that starts in the bladder; 90% is transitional cell carcinoma, 5-7% is squamous cell carcinoma, and 1-2% is adenocarcinoma/urachal carcinoma.

Classification of bladder cancers

- I. *Papillary tumors*: have a wart-like appearance and are attached to a stalk
- II. *Nonpapillary (sessile)*: tumors are much less common, but more invasive and have a worse outcome

Signs and symptoms

- Painless
- Gross haematuria is the commonest presentation
- Microscopic haematuria
- Irritative voiding symptoms

Causes/Risk factors

- Cigarette smoking
- Age
- Cyclophosphamide
- Phenacetin
- Chemical exposure at work – carcinogens (dye workers, rubber workers, aluminum workers, leather workers, truck drivers, and pesticide applicators)
- Chemotherapy
- Radiation treatment
- Bladder infection

Diagnosis

- Clinical
- Investigations
- Urine cytology
- Cystoscopy
- Upper tract/abdominal/pelvic evaluation with CT scan or intravenous pyelography (IVP)
- TURBT for tissue diagnosis (Histopathological analysis)

Note:

If tests confirm bladder cancer, staging is done to see if the cancer has spread. Staging helps guide future treatment and follow-up and gives idea on patient prognosis.

The TNM (Tumor, Nodes, Metastasis) staging system of bladder cancer:

- Stage 0 - Noninvasive tumours that are only in the bladder lining
- Stage I - Tumour goes through the bladder lining, but does not reach the muscle layer of the bladder
- Stage II - Tumour goes into the muscle layer of the bladder
- Stage III - Tumour goes past the muscle layer into tissue surrounding the bladder
- Stage IV - Tumour has spread to neighboring lymph nodes or to distant sites (metastatic disease)

Management

- Treatment depends on the stage of the cancer, the severity of disease symptoms and overall health

- Stage 0 and I treatments
 - Surgery to remove the tumor without removing the rest of the bladder
 - Chemotherapy or immunotherapy directly into the bladder
- Stage II and III treatments
 - Surgery to remove the entire bladder (radical cystectomy)
 - Surgery to remove only part of the bladder, followed by radiation and chemotherapy
 - Chemotherapy to shrink the tumor before surgery
 - A combination of chemotherapy and radiation (in patients who choose not to have surgery or who cannot have surgery)

Most patients with **stage IV** tumors cannot be cured and surgery is not appropriate. In these patients, chemotherapy is often considered.

Treatment Summary

- Superficial bladder cancer and carcinoma in situ (Intravesical chemotherapy with mitomycin C, intravesical immunotherapy with BCG)
- Perform radical cystectomy with urinary diversion; for BCG failure in carcinoma in situ, for muscle invasive disease
- Neo adjuvant chemotherapy to down stage tumours for unresectable to resectable
- Chemotherapy for advanced disease

7.7.3. Cystocele

Definition: Is a medical condition that occurs when the tough fibrous wall between a woman's bladder and her vagina is torn by childbirth, allowing the bladder to herniate into the vagina.

Causes

- Muscle straining during delivery
- Heavy lifting or repeated straining during bowel movements
- Oestrogen deficiency due to old age

Signs and symptoms

- Urine leakage
- Incomplete emptying of the bladder
- Bladder emptying impaired
- Frequency
- Nocturia
- Stress incontinence
- Relaxation of the anterior vaginal wall and descent of the urethra and bladder when the patient strains to void

Investigations

- Urinalysis
- Ultrasonography

Management

- Mesh sling technique
- Transobturator tape (TOT)
- Transvaginal tape (TVT)
- Anterior colporrhaphy

7.7.4. Urinary Incontinence**Definition:** Is the involuntary loss of urine**Classification****Classification of incontinence according to anatomical abnormality**

Class	Sub- class	Causes/risk factors	Signs and symptoms
Urethral incontinence	Urethral abnormalities	Urethral incompetence Incontinence less common in men after prostatectomy or pelvic fracture	Involuntary urine loss
	Bladder abnormality	Inhibited detrusor contractions by: Neuropathic (detrusor hyperreflexia) non neuropathic (detrusor instability)	Frequency and urgency (urge incontinence)
	Non urinary abnormalities(in elderly patients)	impaired mobility Impaired mental function	
Non urethral incontinence		Fistula Ureteral ectopia	

Classification of incontinence according to clinical presentation

Stress incontinence		Ref. anatomical classification	Ref. anatomical classification
Urge incontinence		Ref. anatomical classification	Ref. anatomical classification
Nocturnal enuresis: bed wetting in older children		Day time voiding abnormalities such as frequency and urgency	
Constant urine wetness		Urinary fistula Ectopic ureter	

Diagnosis

- Detailed history
- Poor flow, hesitancy
- Post micturation dribble (outflow obstruction)
- Dysuria (infection)
- Hematuria (possibility of tumour)
- Sexual function (males), bowel function (both sex) point toward neurological cause
- Mobility and mental status (incontinence in elderly)
- Past or present illness (diabetes, surgery e.g. abdominal perineal resection, hysterectomy DRE for the prostate in male)
- DVE for female for cystourethrocele
- Neurological assessment

Investigations

- RFT
- Urine microscopy and culture
- IVU
- Urodynamics
- Cystometry
- Cystoscopy
- Cystogram

Management

- If urge incontinency
 - Treat the underlying cause
 - Pharmaceutical therapy: anticholinergic and/or smooth muscle relaxant (oxybutynin, emepronium carageenate, flavoxate hydrochloride) associated with bladder exercise
- Surgical therapy
 - Cystoscopy and bladder distention
 - Partial bladder denervation by subtrigonal phenol injection or pre sacral neurectomy
 - Augmentation cystoplasty (bladder enlargement) or substitution cystoplasty (bladder substitution)
 - Urinary diversion (ileal conduit)
- If stress minor incontinence
 - Pelvic floor exercise
 - Estrogen therapy
 - Sympathomimetics (ephedrine or alpha adrenergic agonist e.g. phenylpropanolamine)

- If stress major incontinence
 - Surgical treatment for female
 - Endoscopic or retropubic uretropexy
 - Vaginal repair (anterior colporrhaphy)
 - Artificial urinary sphincter
 - Surgical treatment for male
 - Artificial urinary sphincter
 - Urinary diversion (if medical treatment fails)
- If nocturnal enuresis
 - Bladder training during the day gradually increasing interval between voiding
 - Voiding last thing at night
 - Lift the child before bed
 - Enuresis alarm
 - Drugs: imipramine (tofranil), propantheline, oxybutynin, desmopressin
 - Augmentation cystoplasty (if failure of medical treatment)

7.8. Disorders of the Kidney and the Ureter

7.8.1. Vesico-Ureteric Reflux

Definition: A congenital condition from the ureteral bud coming off too close to the urogenital sinus on the mesonephric duct which result in short intravesical length (intramural) of ureter. Urine travels retrograde from the bladder into the ureter and often into the kidney.

Signs and symptoms

- Evaluate
- Any child with febrile urinary infection
- Any boy with urinary infection
- Any girl with recurrent UTI

Investigations

- Ultrasonography
- Voiding cystourethrogram
- Hereditary, be suspicious in siblings and screen with imaging studies

Management

- Low grade reflux
- Conservative treatment with observation and antibioprohylaxis
- Close follow up
- Treat voiding dysfunction
- High grade reflux
- Surgical intervention with ureteral re-implantation

7.8.2. Calculus

Calcium stones (Ca oxalate, Ca phosphate) are the most common types in 70% of the cases.

Causes

- Renal infections
- Inadequate urinary drainage and urinary stasis
- Prolonged immobilization
- Decreased urinary citrate
- Dietetic (deficiency of vitamin A)
- Altered urinary solutes and colloids
- Hyperparathyroidism

Signs and symptoms

- Asymptomatic (non obstructive renal stones)
- Flank pain (colicky radiating to the lateral abdomen- proximal ureteral stones or pain that irradiate into the groin and genitals- distal ureteral stones)
- Microscopic or gross hematuria
- Obstructive pyelonephritis (signs of sepsis)

Investigations

- Kidney/Ureter x-ray
- Bladder x-ray
- Abdominal ultrasound

Management

- Extracorporeal shock wave lithotripsy (ESWL) if non obstructive renal stones less than 2.5 cm
- Percutaneous nephrolithotomy (PCNL), if large renal stone
- Percutaneous removal if Staghorn calculi
- Cystoscopy with stent placement

7.8.3. Renal Cell Carcinoma

Occurs in young adults

Signs and symptoms

- A triad of pain hematuria and frank mass
- Weight loss
- Fever
- Erythrocytosis
- Left sided varicocele
- Hypertension
- Paraneoplastic syndromes (hypercalcemia, hypertension, polycythemia and Stauffer's Syndrome)

Complications

- RCC can extend into renal vein, up the IVC (inferior vena cava) and into the atrium.

Management

Palliation

- Renal artery embolisation (may stop hematuria)
- Chemotherapy (10% response rate)
- Hormonal therapy (5% response rate)
- Immunotherapy (under review)

Surgery

- Partial nephrectomy, if small peripheral lesions
- Radical nephrectomy (Gerota's fascia and regional lymphnodes)
- Isolated lung metastases should also be removed surgically

7.8.4. Nephroblastoma or WILMS TUMOURS

Definition: It is the most common solid renal tumour in childhood, accounting for roughly 5% of childhood cancers. It is an embryonic tumour arising from nephrogenic tissue.

Signs and symptoms

- An abdominal mass (incidental)
- Abdominal pain and distention

- Fever/ convulsions
- Cough
- Anorexia
- Nausea and vomiting
- Hematuria (in about 20% of cases)
- High Blood Pressure in 25 – 60%
- Coagulopathy can occur in 10%

Investigations

- FBC
- Renal function test
- Liver function test
- An Ultrasound
- CT scan or MRI
- Chest x-ray
- Plain abdominal x-ray
- IVP
- Surgical biopsy

Management

- If unilateral tumours
 - chemotherapy: Adriamycin, vincristine or doxorubicine for 52 weeks followed by
 - nephrectomy
- If bilateral tumours
 - Partial nephrectomy and chemotherapy
 - Radiotherapy

7.8.5. Pelvi-Ureteric Junctions

Definition: Blockage of the ureter where it meets the renal pelvis.

Cause

- Congenital from either abnormalities of the muscles itself or crossing vessels.

Signs and symptoms

- Abdominal mass in the new born
- Flank pain and infection in later life

Investigations

- Ultrasound
- Diuretic renal scan

Management

- Pyeloplasty (Anderson- Hayne)

7.8.6. Tumours of the Renal Pelvis and Ureter

They are relatively rare. They account for approximately 10% of all renal tumours and approximately 5% of all urothelial tumours.

Causes/risk factors

- Tobacco smoking
- Drinking coffee (observed for people who take > 7cups of coffee/day)
- Analgesic abuse
- Chronic infections, irritations
- Hereditary

Signs and symptoms

- Painless intermittent hematuria
- Clot colic
- Loin pain
- Anorexia
- Dysuria
- Weight loss
- Abdominal mass palpable in 5%

Investigations

- Urine cytology
- IVU
- Ultrasonography
- Retrograde ureterography
- Antigrade pyelography
- CT scan
- Chest x-ray
- Cystoscopy
- Ureteroscopy

Management

- Nephro ureterectomy and partial cystectomy
- Chemotherapy in case of lymphnode metastases

7.8.7. Urine Retention

Definition: It is a sudden and painful inability to pass urine voluntarily when the bladder is full (acute UR) or painless retention with sometimes overflow incontinence (Chronic UR).

Causes

- Obstructive
- Benign prostatic hyperplasia
- Cancer of prostate
- Urethral stricture
- Bladder neck obstruction
- Trauma of the pelvis
- Phymosis
- Pelvic masses and gynecology malignancies
- Infectious and inflammatory
- Acute prostatitis
- Vulvovaginitis
- Neurologic
- Spinal and peripheral nerve injuries
- Spinal compression
- Cerebrovascular disease
- Guillain Barre Syndrome
- Diabetes mellitus
- Tumours
- Pharmacologic
- Anticholinergics and alphasadrenergic agents

Signs and symptoms

- Painful urge to pass urine
- Dysuria
- Increased frequency
- Uncontrolled dribbling of urine through the urethra

Investigations

- Blood urea and serum creatinine
- Urinalysis, culture and sensitivity

- Ultrasonography
- CT scan brain, spine, pelvis if suspicion of neurologic lesion
- Plain x-ray

Management

- Bladder drainage (emergency)
- Aseptic catheterization
- IV fluid replacement if rapid decompression syndrome (hematuria, hypotension or post-obstructive diuresis)
- Antibiotics if infected urine: fluoroquinolones (ciprofloxacin) and wait for urine culture and sensitivity

Complication

- Chronic renal failure

7.8.8. Vesicovaginal Fistula

Causes

- Obstetric: The usual cause is protracted or neglected labor
- Gynecological: The operation chiefly causing this complication are total hysterectomy and anterior colporrhaphy
- Radiotherapy: Direct neoplastic infiltration
- Exceptionally: Carcinoma of the cervix ulcerates through the anterior fornix to implicate the bladder

Signs and symptoms

- Leakage of urine from the vagina
- Excoriation of the vulva
- Vaginal examination may reveal a localized thickening on its anterior wall or in the vault
- On speculum: urine escaping from an opening in the anterior vaginal wall

Investigations

- The three-swab test
- Cystoscopy
- Bilateral retrograde ureterography
- IVU

Management

- Conservative management: Bladder drainage
- Surgical repair
- Low fistula (subtrigonal): Transvaginal repair. A urethral catheter should be left in situ for at least 10 days
- High fistula (supratrigonal): Suprapubic approach

7.9. Neonatal Obstructive Uropathies

7.9.1. Posterior Urethral Valves

Definition: Obstructive urethral lesions usually diagnosed in male newborns and infants. They are thin membranous folds located in the prostatic urethra.

Cause and Risk factors

- Congenital

Signs and symptoms

- Asymptomatic till adolescence or childhood in incomplete valves
- Urinary retention
- Weak stream
- Dysuria (infection)
- Able to pass catheter without difficulty

Investigations

- Urinalysis
- Ultrasound scan
- Voiding cystogram (dilatation of the urethra above the valves)

Management

- Detect and treat early to avoid renal failure
- Suprapubic catheter
- Transurethral resection

7.9.2. Urethral Stricture

Definition: Congenital narrowing of the urethra

Cause

- Duplication of the urethra.

Signs and symptoms

- Rare and delayed till adolescence
- Indistinguishable from a stricture due to unrecognized urethra infection in childhood

Investigations

- Urinalysis
- RFT
- FBC
- Ultrasonography
- Urethrogram
- IVU

Management

- Treatment infections
- Dilatation
- Optical urethrotomy

7.10. Non traumatic Urological Conditions

7.10.1. Benign Prostatic Hyperplasia (BPH)

Definition: Is a pathologic disorder that develops in response to the action of dihydrotestosterone on the aging prostate and to changes in stromal and epithelial cells in this exocrine gland. BPH never progresses to carcinoma.

Causes

- Idiopathic
- Predisposing factors: age, normally functioning testes, sexual behavior, diet, alcohol, tobacco (no evidence that they play a part)

Signs and symptoms

- Nocturia
- Urinary urgency and frequency
- Acute urinary retention
- Urinary tract infections
- Renal failure
- Urinary stones
- Haematuria

Management

Conservative management

Medical therapy

- Alpha Blockers: e.g.
- Androgen suppression: e.g.

Surgery

- Trans urethral microwave thermotherapy
- Transurethral needle ablation
- Trans-urethral Resection prostate (TURP)
- Open surgery: Prostatectomy

7.10.2. Adenocarcinoma

Definition: Adenocarcinoma is a cancer originating in glandular epithelial tissue. Epithelial tissue includes, but is not limited to, skin, glands and a variety of other tissue that lines the cavities and organs of the body.

Causes/Risk factors

- Age: is the most powerful risk factor
- Family history: first degree relative with the disease implies a twofold increased risk

Investigations

- PSA is used in conjunction with DRE to enable early detection of the disease and detect biochemical disease recurrence following treatment
- Patient with an elevated PSA and/or abnormal DRE are recommended to undergo TRUS guided biopsy

- Metastatic work up in selected patient based on clinical picture
 - CT scan of the Bones
 - MRI of the bones

Management

- Brachytherapy, external beam radiation therapy or radical retropubic prostatectomy for patients with localized prostate cancer
- Definitive therapy for patients expected for greater than 10 year survival
- At the time of prostatectomy, a pelvic lymphadenectomy is performed first
- Consider systemic therapy (androgen deprivation therapy and hormonal therapy) for patients with significant co-morbidities and/or more extensive diseases

7.10.3. Bladder Cancer

Definition: Bladder cancer is a cancer that starts in the bladder. It is of two forms, transitional cell carcinoma (> 90%) and squamous cell carcinoma (5-7%).

Causes/Risk factors

- Cigarette smoking
- Chemical exposure at work (carcinogens - dye workers, rubber workers, aluminum workers, leather workers, truck drivers, and pesticide applicators)
- Chemotherapy (e.g. cyclophosphamide)
- Radiation treatment
- Chronic bladder infection or irritation (e.g. schistosomiasis)

Signs and symptoms

- Gross painless haematuria (most common)
- Microscopic haematuria
- Irritative urine voiding symptoms
- Bone pain or tenderness

Investigations

- Urinalysis
- Cystoscopy
- Intravenous pyelography (IVP)
- TURBT for tissue diagnosis (Histopathological analysis)

- Intravenous pyelogram - IVP
- CT scan of the upper urinary tract Pelvic CT scan

The TNM (Tumor, Nodes, Metastasis) staging system of bladder cancer

- Stage 0 - Noninvasive tumours that are only in the bladder lining
- Stage I - Tumour goes through the bladder lining, but does not reach the muscle layer of the bladder
- Stage II - Tumour goes into the muscle layer of the bladder
- Stage III - Tumour goes past the muscle layer into tissue surrounding the bladder
- Stage IV - Tumour has spread to neighboring lymph nodes or to distant sites (metastatic disease)

Complications

- Anemia
- Hydronephrosis
- Urinary incontinence

Management

Treatment depends on the stage of the cancer, severity of symptoms, and overall health of the patient.

Treatment for Stage 0 and 1

- Surgery to remove the tumour without removing the rest of the bladder
- Chemotherapy or immunotherapy directly into the bladder

Treatment of stage II and III

- Chemotherapy to shrink the tumour before surgery
- Radical cystectomy
- Surgery to remove only part of the bladder, followed by radiation and chemotherapy
- A combination of chemotherapy and radiation (in patients who choose not to have surgery or who cannot have surgery)

Note:

Most patients with **stage IV** tumours cannot be cured and surgery is not appropriate. In these patients, chemotherapy is often considered

Treatment summary

- Intravesical chemotherapy with mitomycin C or intravesical immunotherapy with BCG): for patients with superficial bladder cancer and carcinoma in situ
- Radical cystectomy with urinary diversion: for BCG failure in carcinoma in situ with muscle invasive disease
- Neo adjuvant chemotherapy: to down stage tumours for unresectable to resectable
- Chemotherapy for advanced disease

7.10.4. Renal Cell Carcinoma

Definition: Renal cell carcinoma is a type of kidney cancer that starts in the lining of the kidney tubules. It occurs in young adults (40-60 years of age).

Causes/Risk factors

- The exact cause is unknown
- Dialysis treatment
- Family history of the disease
- High Blood Pressure
- Horseshoe kidney
- Polycystic kidney disease
- Smoking
- Von Hippel-Lindau disease

Signs and symptoms

- Classic presentation: A triad of pain hematuria and frank mass
- Other presentations: Includes weight loss, fever, erythrocytosis, left sided varicocele and hypertension
- Paraneoplastic syndromes in 20% of patients (hypercalcemia, hypertension, polycythemia and Stauffer's Syndrome)
- Non metastatic hepatic dysfunction
- Mass or swelling of the abdomen

Investigations

- Chest x-ray and CT scan
- Abdominal CT scan
- Abdominal MRI
- Bone scan
- PET scan

Management

- Radical nephrectomy include Gerota's fascia and regional lymphnodes
- Isolated lung or liver metastasis resection
- Partial nephrectomy (reserved for small peripheral lesions or in patient with solitary kidneys or bilateral tumours)

Note:

RCC can extend into renal vein, up the IVC and into the atrium

8. Burns

Definition: Burns are skin and tissue damage caused by exposure to or contact with temperature extremes, electrical current, a chemical agent or radiation.

Causes

- Thermal causes; hot or cold exposure or contact with objects or liquids
- Chemical or caustic substances
- Electrical current

Symptoms and signs

- Pain when superficial
- Painless when very deep
- Discolored skin (black, red when superficial, white when very deep)
- Blisters (superficial burns)
- Moist, wet wound in skin
- Smell of burnt flesh
- Loss of skin

Assessment of burns

- Primary survey: ABC's
 - Stop the burning process
 - Airway – Check for erythema and oedema of airway, to anticipate possible need for early intubation
 - Breathing – (Beware of inhalation and rapid airway compromise)
 - Circulation – (Good IV access fluid replacement)
 - Disability – (GCS, Compartment Syndrome)
 - Exposure – (% burn)

Note:

Nasotracheal or endotracheal intubation is indicated especially if patient has a severe increase in hoarseness, difficulty swallowing secretions, or increased respiratory rate with history of inhalation injury.

- Secondary survey
 - Coincident trauma diagnosed and treated
 - Burns are further characterized by estimating extent of burn depth

- First-degree
 - Superficial (sunburn)
 - Erythema, pain, absence of blisters
 - Consists of epidermal damage alone

- Second-degree
 - Entire epidermal layer
 - Part of underlying dermis
 - Mottled and red, painful, swelling and blisters

- Third-degree (Full thickness)
 - Injury/destruction of all epidermal and dermal elements
 - Burn into subcutaneous fat or deeper
 - Skin is charred and leathery (woody)
 - Pearly-white sheen / waxy
 - Generally NOT painful (nerve endings are dead)

- Fourth-degree
 - Full-thickness
 - Extending into muscle, tendons or bones
 - Typically involves appendage
 - Black and dry
 - NOT painful

- Use rule of nine to estimate the extent of burn

Management

Use Parkland formula for fluid replacement: % TBSA burned) x (Weight in kg) x (4 ml lactated Ringer's/kg:

- Administer the first half of the volume in the first 8 hrs, then administer the second half of the volume in the following 16 hrs
- The timing starts when the burn occurred and not when the patient arrived in the treatment facility
- Measure URINE INPUT and OUTPUT (output of 0.5 ml/kg/hr in adults and 1 cc/kg/hr in children)
- Use Lactated Ringer's solution

- Endpoints for Fluid Resuscitation
 - Hourly Urine Output
 - Heart Rate, Blood Pressure
 - Acid-Base Status
 - Filling Pressure (CVP, PAWP)

Burn Wound Treatment

- Clean the burn area with mild normal saline for clean wounds, and hypertonic solution for infected wounds
- debridement of devitalized tissue and debris
- Apply topical antibacterial agent:
 - Bacitracin ointment on face / ears
 - Silver sulfadiazine on the body
 - Ensure aseptic procedures
- Escharotomy: when pulse less extremity with a circumferential burn
- Ensure effective pain management
- Provide tetanus prophylaxis to all burn patients. If without current tetanus immunization, requires tetanus immune globulin (TIG)
- Give antibiotic for infected wounds: IV cloxacilline 100mg/kg in children and 3gm in adults (in three divided doses per day, 5-7days)

8.1. Electrical Burns

Definition: Electrical burns are body injuries caused by electrical current itself. The current generates intense heat along its path through the body, which can lead to severe muscle, nerve and blood vessel damage.

Causes

- Lightning strikes and generated electrical power
- Exposure to electrical flow

Signs and symptoms

- Cardiac and respiratory arrest
- Intracranial hemorrhage and coma
- Blunt trauma
- Severe burns

Investigations

- CBC – Hemoglobin, hematocrit, white blood cell count
- Electrolytes – Sodium, potassium, chloride, carbon dioxide, blood urea nitrogen, glucose
- Urinalysis – Specific gravity, pH, hematuria, and urine myoglobin if urinalysis is positive for hemoglobin
- A baseline assessment of muscle damage is established with Total CPK (followed by
- CPK isoenzymes (if total CPK is elevated)
- Urine myoglobin (followed by serum myoglobin if urine myoglobin is present) Creatinine – High risk of rhabdomyolysis/myoglobinuria and creatine kinase (CK) levels
- Serum myoglobin – If urine is positive for myoglobin, a serum level should be obtained
- Arterial blood gas – To be obtained for patients needing ventilatory support, or those with severe rhabdomyolysis who require urine alkalinization therapy
- Chest radiography
- CT scan of the head and spine
- MRI of the head and spine

Complications

- Peripheral nerve injury
- Vascular damage
- Acute pulmonary complications
- Abdominal complications
- Bone lesions
- Multiple organ injuries

Management

- It is important to establish the type of exposure (high or low voltage), duration of contact, and falls or other trauma.
 - Hydration is the key to reducing the morbidity of electrical injuries
 - Osmotic diuretic if muscle damage is significant
 - Initial IVF resuscitation is with LR, up to 10cc/kg/hr
 - Mannitol or furosemide to the fluid regimen of patients with elevated CPK and/or myoglobinemia

Note:

These drugs provide diuresis for the toxic myoglobin, which can help prevent acute tubal necrosis and renal failure secondary to myoglobinuria.

9. Bites and Stings of Animals and Insects

9.1. Animal Bites

Definition: Animal bites are wounds inflicted on the body due to animals sinking teeth into one's body. Animal bites and scratches, even when they are minor can become infected and spread bacteria to other parts of the body. Whether the bite is from a family pet or an animal in the wild, scratches and bites can carry disease. Some animals can transmit rabies and tetanus.

Animal Type	Evaluation and Disposition of Animal	Post-exposure Prophylaxis Recommendations
Dogs and cats	Healthy and available	Should not begin prophylaxis, 10 days observation, unless animal develops symptoms of rabies
	Rabid or suspected rabid	Immediate vaccination (consider also tetanus toxoids)
	Unknown (escaped)	Consult public health officials
Skunks, raccoons, bats, foxes, and most other carnivores; woodchucks	Regarded as rabid unless geographic area is known to be free of rabies or until animal proven negative by laboratory tests	Immediate vaccination
Livestock, rodents, and lagomorphs (rabbits and hares)	Consider individually	Consult public health officials; bites of squirrels, hamsters, guinea pigs, gerbils, chipmunks, rats, mice, other rodents, rabbits, and hares almost never require anti-rabies treatment

9.2. Rabies

Definition: Rabies is a deadly viral infection that is mainly spread by infected animals.

Causes

Rabies is spread by infected saliva that enters the body through animal bite or broken skin

Animals known to spread rabies are:

- Dogs
- Bats
- Raccoons
- Foxes
- Skunks

The average incubation period is 3 - 7 weeks

Signs and symptoms

- Paresthesia
- Headache
- Stiff neck
- Lethargy
- Pulmonary symptoms
- Maniacal behaviour
- Muscle spasm of throat with dysphasia
- Convulsion →coma →paralysis →death

Investigations

- immunofluorescence is used to look at the brain tissue after an animal is dead
- Pieces of skin and saliva analysis for presence of rabies

Complications

- Coma and death
- Allergic reaction to the rabies vaccine (rare)

Management

- Local care
 - Thorough irrigation
 - Cleansing with soap solution
- Debridement bite site
- Human Rabies Immunoglobulin (HRIG), given the day the bite occurred
- Antibiotics in case of infection
- Rabies Vaccination in 5 days over 28 days
 - Rabies vaccine adsorbed (RVA) (Imovax)
 - Human diploid cell rabies vaccine (HDCV)
 - Either administered with HRIG (Imogan rabies)
 - Vaccine administered intramuscularly in deltoid area for adult and anterolateral aspect of thigh for children

Recommendations

- Most of the time, stitches should not be used for animal bite wounds
- Immunization and treatment for possible rabies are recommended for at least up to 14 days after exposure or a bite

9.3. Snakebites and Venom

Definition: Poisonous snakes inject venom using modified salivary glands

The venom apparatus

Venomous snakes of medical importance have a pair of enlarged teeth, the fangs, at the front of their upper jaw. These fangs contain a venom channel (like a hypodermic needle) or groove along which venom can be introduced deep into the tissue of their natural prey. If a human is bitten, venom is usually injected subcutaneously or intramuscularly. Spitting cobras can squeeze the venom out of the tips of their fangs, producing a fine spray directed toward the eyes of an aggressor.

Causes

- Crotalidae or pit vipers snakes
- Coral snakes of the elapidae family
- Snakes with elliptical pupil
- Snakes with single row of sub caudal plates

Signs and symptoms

- Eyes (spitting cobras and ringhals can eject their venom quite accurately into the eyes of the victims, resulting in direct eye pain and damage)
- Swelling and tissue damage
- Suddenly develop breathing difficulty and go into shock
- Local effects (swollen, bleeding, blister and gangrene)
- Nervous system effects (vision problems, speaking and breathing trouble, and numbness close to or distant to the bite site, and death without treatment)
- Muscle death (muscle necrosis, rhabdomyolysis, kidney failure)

Diagnosis

- History and clinical presentation

Signs and symptoms

- Hypotension
- Weakness
- Nausea/vomiting
- Pain, swelling, tenderness and ecchymosis at site of bite
- Paresthesia and muscle fasciculations
- Defect in blood coagulation
- Pulmonary edema

Grading of envenomation

Grade	Signs and Symptoms
0 – No envenomation	Fang marks, minimal pain, small edema and erythema
I – Minimal Envenomation	Fang marks, moderate to severe pain, surrounding edema and erythema
II – Moderate Envenomation	Fang marks, severe pain, edema, erythema, possible systemic involvement (nausea, vomiting, shock)
III – Severe Envenomation	Fang marks, large surrounding edema and erythema with generalized petechiae and ecchymosis
IV – Very severe Envenomation	Systemic effect present. Symptoms may include renal failure, coma and death

Complications of snake bites

- The injection of even highly purified serum carries a risk of untoward reactions. The most common is serum sickness which may occur about ten days after the injection but sometimes sooner. It is characterized by itching rashes and sometimes a rise in temperature and joint pains. Proper treatment (antihistaminics, steroids) should alleviate the symptoms.
- A rare but far more serious complication is an acute serum reaction (anaphylaxis) with a sudden drop in Blood Pressure and collapse within a few minutes. The risk of this type of reaction in a healthy person is very slight but those with an allergic disposition, in particular a history of asthma or infantile eczema, should not receive serum unless it is absolutely necessary and then only with the greatest caution. Treatment for this condition includes the injection of adrenalin.

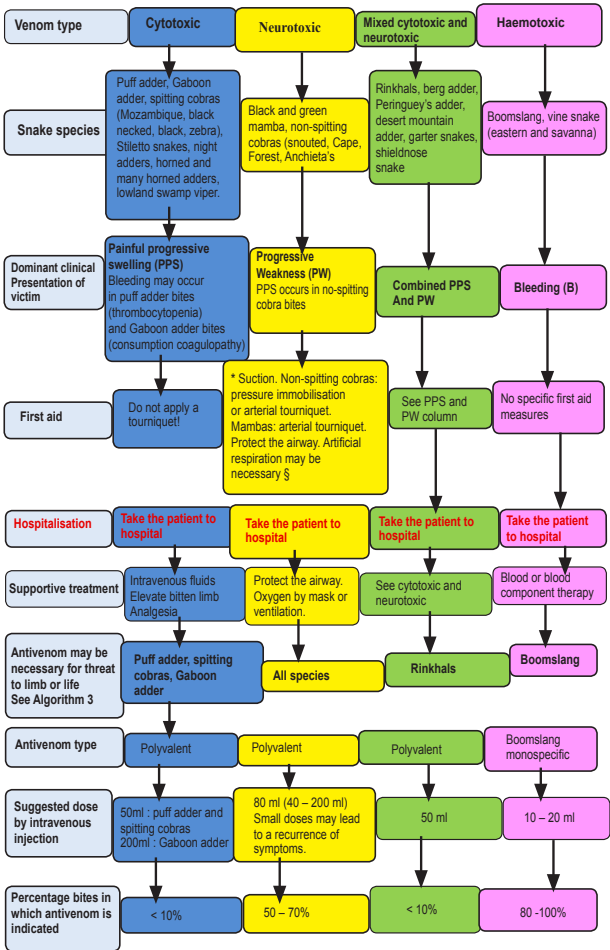
Management of snake bites

- Application of a tourniquet, incision and suction are appropriate if done within one hour from time of bite
- Antivenon (crotalidae polyvalent immune)
- The dose of anti-venom serum required depends on the amount of venom injected by the snake, not on the size or mass of the victim, and should not be reduced in the case of children
- The initial doze should be large; at least contents of 20 ml, but the condition of the patient may demand the injection of up to 4 or 5 times as much
- When given intravenously, the venom serum should be at room temperature, and the injection given very slowly, with the patient recumbent during injection, and at least one hour afterwards
- IVF required to replace the decreased extra cellular fluid volume resulting from edema formation
- Fascial planes may become tense with obstruction of venom and later arterial flow, requiring fasciotomy
- Vit K may be required to correct bleeding and clotting abnormalities
- Tetanus toxoid administered and antibiotics recommended to prevent secondary infection

Recommendations

- Serum treatment, although not imminently urgent, may become necessary, a trial dose of 0,1 mL of serum diluted 1:10 in sterile saline or water could be injected under the skin. If there is no untoward reaction within 30 minutes, 0,2 mL of undiluted serum could be given in the same way, to be followed, if necessary, by the full dose if no reaction occurs to this trial dose
- Where possible, whenever serum is to be injected, the patient should be kept under observation for at least 30 minutes after the injection, and adrenalin and corticosteroid kept in readiness for emergency use

Summarized chart for management of snakebites



6 Bites and Stings of Animals and insects

9.4. Insect Stings

Definition: A sting is usually from an attack by a venomous insect such as a bee or wasp, which uses this as a defence mechanism by injecting toxic and painful venom through its stinger. Insect bites and stings can be divided into 2 groups namely: venomous and non-venomous. Non-venomous insect bites pierce the skin to feed on blood, this usually results in intense itching.

Causes of insect bites and stings

Venomous (stingers)	Non-venomous (biters)
Fire ants	Bed bugs
Yellow jackets	Fleas
Hornets	Ticks
Wasps	Lice
Bees	Scabies
	Caterpillars and moths
	Mosquitoes

Signs and Symptoms

- Localized pain
- Petechial hemorrhages
- Swelling of skin and mucus membrane
- Generalized erythema
- Abdominal cramps
- Pulmonary and cerebral edema
- Blurred vision
- Vascular collapse
- Death results from combination of shock
- Respiratory failure and CNS changes
- Most death from insect stings occur within 15 to 30 minutes
- Early application of a tourniquet may prevent rapid spread of venom
- Emergency kit containing epinephrine commercially available

9.5. Spider Bites

Definition: Spider bite is the puncture wound produced by the bite of a spider.

Signs and symptoms

Generalized muscle spasm is the most prominent physical finding.

- Priapism and ejaculation (have been reported)
- Severe bite results in necrosis and sloughing of skin with residual ulcer formation
- Pathophysiology of bite: intravascular coagulation → formation of micro thrombi → capillary occlusion → hemorrhage → necrosis
- Fever, nausea, vomiting, headache, weakness, arthralgia, malaise, petechiae
- Hemolysis and thrombocytopenia responsible for death

Treatment

- Narcotics for pain
- Muscle relaxant for relief of spasm
- Calcium gluconate relieves most symptoms

Note:

Most patients recover within 24 hours

10. References

1. Ashford RU, Mehta JA, Cripps R. Delayed presentation is no barrier to satisfactory outcome in the management of open fractures. *Injury*; 2004; 35:411-416.
2. Barbara A Latenser, MD *Critical Care of the Burn Patient: The First 48 Hours*, Crit Care Med. 2009;37(10):2819-2826
3. Blaylock R. *Epidemiology of snakebite in Eshowe*, KwaZulu-Natal, South Africa. *Toxicon* 2004 ; 43 (2): 159 – 66
4. Blaylock RS. Antibiotic use and infection in snakebite victims. *S Afr Med J* 1999; 89 (8): 874 – 6
5. *AO principles of fracture management* (2007) Editors-in-Chief T. P. Rüedi W. Murphy. Editors C. L. Colton A. Fernandez Dell’Oca J. F. Kellam U. Holz.
6. Blaylock RSM. *Acute adverse reactions to South African manufactured snakebite antivenom*. *Current Allergy & Clinical Immunology* 2002: 15 : 107 – 13
7. Blaylock RSM. Antibacterial properties of KwaZulu Natal snake venoms. *Toxicon* 2000; 68:1529 – 34
8. Blaylock RSM. *Normal oral bacterial flora from some Southern African snakes*. *Ondestepoort Journal of Veterinary Research* 2001; 68: 175– 82
9. S. Terry Canale (1998): *Campbell’s Operative Orthopaedics*, 9th Edition
10. Chaaralambour CP, Siddique et al. Early versus Delayed Surgical Treatment of open Tibial Fractures; effects on the rate of infection and need of secondary surgical procedures to promote bone union. *Injury* 2005; 36:656-661.
11. Chitra S. Mani and Dennis L. Murray. Rabies. *Pediatr. Rev.*, Apr 2006; 27: 129 - 136.
12. Coetzer PWW, Tilbury CR. *The epidemiology of snakebite in Northern Natal*. *S Afr Med J* 1982; 62: 206 – 12.
13. *Current orthopaedics* 4th Edition (2006) Harry B. Skinner, MD, PhD is Professor and Chairman of the Department of Orthopaedic Surgery at the University of California, Irvine
14. Edwards IR, Fleming JBM, James MFM. *Management of a Gaboon viper bite : a case report*. *Cent Afr J Med* 1979; 25: 217 – 21

15. Evans EI, Purnell OJ, Robinett PW, et al: *Fluid and electrolyte requirements in severe burns*. Ann Surg 1952; 135:804–815
16. *Fractures of the Pelvis and Acetabulum* 2nd Edition Marvin Tile/Baltimore, Williams and Wilkins, 1995.
17. Gross T et al.: *Multiple-trauma management: standardized evaluation of the subjective experience of involved team members*. European Journal of Anaesthesiology (2005), 22: 754-761
18. Henley MB, Chapman JR, Agel J et al. *Treatment of Type 1, 11A, 111B open fractures of Tibial Shaft a Prospective comparison of interlocking intramedullary nails and half-pin external fixators*. Journal of Orthopedic Trauma 1998; 12:1-7.
19. Herndon DN (Ed): *Total Burn Care*. Philadelphia, Elsevier Saunders, 2007
20. Jane Curtis. *Insect Sting Anaphylaxis*. Pediatr. Rev., Aug 2000; 21: 256.
21. KanuOkike, BA and Timothy Bhattacharyya MD, *Trends in Management of Open Fractures, A Critical Analysis*. The American Journal of Bone and Joint Surgery 2006; 88:2739 – 2748.
22. Kauvar D, Lefering R & Wade C (2006) *Impact of Hemorrhage on Trauma Outcome: An Overview of Epidemiology, Clinical Presentations and Therapeutic Considerations*, 60 (6): S3-S11
23. Malasit P, Warrell DA, Chanthavanich P, Viravan C, Mongkolsapaya J, Singthong B, Supich C. *Prediction, prevention, and mechanism of early (anaphylactic) antivenom reactions in victims of snake bites*. Br Med J 1986 292: 17 – 20
24. McNally SL, Reitz CJ. *Victims of snakebite: A 5-year study at Shongwe Hospital, Kangwane, 1978 – 1982*. S Afr Med J 1987; 72: 855 – 60
25. Moppett IK: *Traumatic brain injury: assessment, resuscitation and early management*. BJA (2007) 99 (1): 18-31.
26. Muller GJ. *Black and brown widow spider bites in South Africa*. S Afr Med J 1993; 83: 399 -405
27. Muller GJ. *Scorpionism in South Africa*. S Afr Med J 1993; 83: 405 – 11 Bergman NJ. *Scorpion sting in Zimbabwe*. S Afr Med J 1997; 87: 163 – 7
28. Patzakis MJ, Bains et al. *Prospective, randomized, double blind study comparing single agent antibiotic therapy ciprofloxacin to combination antibiotic therapy in management of open fracture wounds*. Journal of Orthopedic Trauma 2000;14:529-533.

29. Phillip L. Rice et al. *Emergency care of moderate and severe thermal burns in adults* ; UpToDate, May 2011
30. Rutland-Brown W, Thomas KE. Traumatic Brain Injury in the United States: Emergency Department Visits, Hospitalizations, and Deaths. Atlanta, Ga: Centers for Disease Control and Prevention; Jan 2006
31. Scharf GM, du Plessis HJC. *Guidelines for the management of puff adder bites*. Trauma Emerg Med 1993; 948 –52
32. The acute abdomen Dr. Ed. Snyder, Dr. Melanie Walker Huntington Memorial... *PAEDIATRIC EMERGENCIES*, Hospital Medicine (2004) vol 65
33. *The South African institute for medical research Serum and vaccine department*, RIET FONTEIN
34. Tilbury, CR. *Observations on the bite of the Mozambique spitting cobra (Najamossambicamossambica)*. S Afr Med J 1982; 61: 308 – 13s; 1996
35. Wilkinson D. *Retrospective analysis of snakebite at a rural hospital in Zululand*. S Afr Med J 1994; 84 (12): 844 – 7
36. Vons C., Barry C., Maitre S et al.: *Amoxicillin plus clavulanic acid versus appendicectomy for treatment of acute uncomplicated appendicitis: an open-label, non-inferiority, randomized controlled trial*. Lancet 2011; 377: 1573-79
37. *Operative Treatment of Femoral Neck Fractures in Patients Between the Ages of Fifteen and Fifty Years*; George J. Haidukewych, MD¹; Walter S. Rothwell, PA-C²; David J. Jacofsky, MD²; Michael E. Torchia, MD²; Daniel J. Berry, MD²
37. Turgut AT, Bhatt S, Dogra VS. *Acute Painful Scrotum*. Ultrasound Clinics. Jan 2008; 3(1). [PubMed]
38. Ringdahl E. Testicular Torsion. Am Fam Physician. Nov 2006; 74 (10): 1739-43. [PubMed]
39. Wein AJ, ed. *Campbell-Walsh Urology*. 9th ed. Philadelphia, Pa: Saunders Elsevier; 2007.
40. Ho K-LV, Segura JW. *Lower urinary tract calculi*. In: Wein AJ, ed. *Campbell-Walsh Urology*. 9th ed. Philadelphia, Pa: Saunders Elsevier; 2007: chap 84.

41. Rupprecht CE, Briggs D, Brown CM, et al. Centers for Disease Control and Prevention (CDC). Use of a reduced (4-dose) *vaccine schedule for postexposure prophylaxis to prevent human rabies: recommendations of the advisory committee on immunization practices*. MMWR Recomm Rep. 2010 Mar 19;59(RR-2):1-9. Erratum in: MMWR Recomm Rep. 2010 Apr 30; 59(16):493. [PubMed]
42. Bassin SL, Rupprecht CE, Bleck TP. Rhabdoviruses. In: Mandell GL, Bennett JE, Dolin R, eds. Principles and Practice of Infectious Diseases. 7th ed. Philadelphia, Pa: Elsevier Churchill Livingstone; 2009: chap 163.
43. Handbook of Neurosurgery, Seventh Edition by Mark S. Greenberg (2010)
44. Principles of Neurosurgery, Second Edition by Setti S. Rengachary (2004)

List of participants

No	Last name	First name	Position
1	MUGENZI	Savio Dominique	Orthopedic-Surgeon
2	MUNEZA	Severien	Neurosurgeon
3	NTAKIYIRUTA	Georges	Surgeon
4	REGINALD	Morcels	Surgeon
5	RWAMASIRABO	Emile	Surgeon (Urology)
6	BITEGA	Jean paul	Orthopedic-Surgeon
7	MUKIMBIRI	Edmond	Orthopedic-Surgeon
8	NKUSI	Emmanuel	Neurosurgeon
9	NSENGIYUNZA	Emmanuel	Orthopedic-Surgeon
10	NYANGEZI	Bonanne	Surgeon (Urology)
11	UWAMAHORO	Florence	Post Graduate (Urology)
12	MUKAMA	Deogratus	Medical Officer
13	KAYIBANDA	Emmanuel	Surgeon
14	FURAHA	Charles	Plastic Surgeon
15	MUKISA	Didas	Thoracic Surgeon
16	NZEYIMANA	Bonaventure	Public Health Facilities Expert
17	ATWINE	Joy	QI Advisor
18	BUTARE	Richard	QI Advisor
19	MANZI	Emmanuel	QI Advisor
20	AHABWE	Moses	Technical Advisor
21	MUNYAMPUNDU	Horatius	QI Advisor

